

# Negative Pressure Wound Therapy: Past, Present, and Future

<sup>1</sup>David C Hatch, <sup>2</sup>Vlad Sauciuc, <sup>3</sup>Emily C Wagler, <sup>4</sup>Brian Schenavar, <sup>5</sup>David Armstrong

## ABSTRACT

From antiquity to today, tissue repair and wound healing have played a central role in health. Over the past generation, negative pressure wound therapy (NPWT) has shown itself to be a valuable adjunct in wound healing, with effects that are superior to many traditional wound treatment modalities. Applications of NPWT are widespread, with use seen in management of severe soft tissue loss, prevention of surgical site infections, treatment of diabetic foot ulcers, and improving skin graft survival. This article reviews the biology, mechanics, and therapeutic effects of NPWT, while also discussing social and economic aspects of use. Finally, various possible adjustments and modifications to NPWT are addressed, all of which contribute to the continual evolution of NPWT at the frontier of modern wound healing and surgery.

**Keywords:** Negative pressure wound therapy, Vacuum-assisted closure; Wound healing.

**How to cite this article:** Hatch DC, Sauciuc V, Wagler EC, Schenavar B, Armstrong D. Negative Pressure Wound Therapy: Past, Present, and Future. *J Foot Ankle Surg (Asia-Pacific)* 2016;3(2):80-87.

**Source of support:** Nil

**Conflict of interest:** None

## INTRODUCTION

### Background

Wound healing dates back several thousand years, with early forms of treatment consisting of plant matter, animal fats, and honey that were found to protect the wound and absorb exudates. It was not until the 18th and 19th centuries that surgery and antiseptic technique became significant aspects of medicine. Modern wound healing techniques were not introduced until the 20th century. Today, wound care is its own medical specialty and there are well over a thousand dedicated wound healing centers in the United States.<sup>1</sup> The medical literature is inconsistent in crediting a person or group of researchers to first use a vacuum-assisted device (VAD)

to aid in wound healing; however, Mouës et al<sup>2</sup> state that Russian researchers in the 1980s appear to be the first to use negative pressure for wound treatment. Lambert et al<sup>3</sup> detail the development of the modern-day negative pressure wound therapy (NPWT), or wound vacuum-assisted closure (VAC). In their outline, they accredit Morykwas and Argenta with the introduction of the commercially available wound VAC (VAC<sup>®</sup> Therapy System, KCI, San Antonio, TX). The same team went on to determine the optimal therapeutic pressures.<sup>2,3</sup> Commercial availability of NPWT has since expanded, and now one of over a dozen systems can be chosen for clinical use. Evaluation of available searchable literature also reveals that since the introduction of NPWT to the clinical environment there have been almost 2,000 published manuscripts concerning its use and efficacy. More than 70 of these studies have been found to include prospective randomized controlled trials. Considering its clinical utility, it is of no small coincidence that there has been such intense interest and investigation into NPWT and its utility in the wound care setting.

### Wound VAC Uses

There are multiple causes, types, and locations for wounds, thus allowing wound VAC therapy a variety of different and unique ways to promote a healthy wound bed. Ozer et al<sup>4</sup> describe cases of severe trauma (a motor vehicle accident and necrotizing fasciitis) to the perineum in which NPWT was used. In the first case, the patient was able to undergo surgery for closure of the wound via free skin flap 6 days after the motor vehicle accident. In this same study, two other patients, each with necrotizing fasciitis and extensive tissue loss, underwent VAC therapy after unsuccessful treatment with alginates, but had a clean wound bed with coverage of granulation tissue after using the wound VAC.

There is an increasing body of data supporting NPWT as an adjunctive modality at all stages of treatment for grade IIIB tibia fractures. Schlatterer and Hirshorn<sup>5</sup> discuss the efficacy of NPWT in preventing infection by comparing the efficacy of silver-impregnated *vs* normal black foam and extending the amount of time an exposed fracture can be uncovered. In a subacute group of open tibia fractures, defined as free flap closure between 8 and 42 days after fracture, the NPWT group had a 35% complication rate and 6% infection rate *vs* 53 and 18% in the

<sup>1-4</sup>Lecturer, <sup>5</sup>Professor

<sup>1-5</sup>Department of Surgery, Southern Arizona Limb Salvage Alliance, University of Arizona College of Medicine, Tucson Arizona, USA

**Corresponding Author:** David Armstrong, Professor, Department of Surgery, Southern Arizona Limb Salvage Alliance, University of Arizona College of Medicine, Tucson, Arizona, USA, e-mail: armstrong.dg@gmail.com

non-NPWT group. The rate of bony union in the subacute fracture was on average 4.9 months in the NPWT group, whereas it was 7.2 months in the non-NPWT group. The authors agree NPWT is not a replacement for surgical debridement or bony stabilization but can be effective as an “active dressing” in removing exudates, preventing dead spaces, and controlling edema.

It is estimated that 1% of the adult population in developed countries and nearly 5% of the population  $\geq 80$  years old suffer from chronic leg ulcers (CLUs).<sup>6</sup> Utilizing standard protocols, only about 50% of these ulcers will heal in  $\leq 4$  months and about 20% will not heal in  $\leq 2$  years, leading to inadequate healing and an increase in inpatient admissions for treatment.<sup>6,7</sup> Vuerstaek et al<sup>8</sup> conducted a study comparing the efficacy of VAC therapy *vs* conventional techniques including compression therapy combined with a hydrogel or alginate dressing. The study found that the median time to complete wound healing was 16 days shorter for patients receiving VAC therapy. It was also concluded in this study that NPWT was less expensive when compared with conventional therapies, patients related higher satisfaction, and endorsed improved quality of life with its use. Furthermore, it was outlined that NPWT use before a skin graft allowed for more rapid achievement of 100% granulation tissue.<sup>8</sup>

Scherer et al<sup>9</sup> investigated the efficacy of NPWT in securing a split thickness graft *vs* a traditional bolster dressing (cotton gauze and bandage with 5% mafenide solution). The study showed that the VAC group had fewer repeated split-thickness skin grafts with many factors thought to be contributing to graft success, such as prevention of hematoma formation or excessive serous fluid accumulation, maintaining a moist environment, and lowering bacterial load and thus decreasing chance of infection. Blume et al<sup>10</sup> found that NPWT is not only more effective compared with advanced moist wound therapy (MWT; alginates and hydrogels) by decreasing time to and percentage of complete closure (14.3%) of diabetic foot ulcers, but also significantly decreases secondary amputation risk.

Lower extremity amputations are a serious complication of diabetes, with 5-year survival rates lower than many forms of cancer. Armstrong et al<sup>11</sup> compared some of the common forms of cancer to diabetes-related amputations, with the 5-year survival rate of diabetic amputations hovering around 50% a far worse prognosis than both breast and prostate cancers, which have 5-year survival rates greater than 80%. The researchers illustrate that ischemic ulcers have the highest mortality and that diabetic ulcers combined with other comorbidities, such as with renal disease requiring distal bypass, have a 5-year survival rate around 5%. The literature is consistent in illustrating the effectiveness and versatility of

NPWT, from increasing wound healing in severe trauma, to saving time and money in treating CLUs, augmenting quality of life, and reducing the rates of amputation and likely also extending the lives of patients with diabetic foot ulcers.<sup>8,10,11</sup>

## NEGATIVE PRESSURE WOUND THERAPY BIOLOGY

### Microphysiology

Negative pressure wound therapy begins working at the microscopic level, creating tension that produces cellular proliferation, increased vascularity, mechanical stresses, and changes in cell signaling by subatmospheric pressure that facilitates favorable wound bed characteristics for healing<sup>12,13</sup> (Fig. 1). Chen<sup>14</sup> conducted research on the mechanical deformity of cells and the effect this has on growth and activation of integrin and growth factor receptors. The researchers found that mechanical stresses alter cellular chemical input, thereby producing changes in the extracellular matrix (ECM) contents due to localized cell tension that extend or expand the cell mass within the local tissue microenvironment. Huang et al<sup>15</sup> further expanded upon these ideas and discuss the effect of NPWT on cell cycles, stating that cell cycle progression (G1 to S) is controlled by tension-dependent changes in cytoskeletal structure and shape, and the progression between cell cycles is directly promoted by the tension applied to a wound in NPWT. Furthermore, the application of NPWT at 125 mm Hg of subatmospheric pressure produces a flattened cell morphology that has been shown to augment fibroblast ability to release energy in the form of adenosine triphosphate (ATP), promote cellular migration toward, and augment collagen filling of the wound defect.<sup>16,17</sup>

McNulty et al<sup>13</sup> studied the effects of subatmospheric pressure on cellular energetics using markers, such as increased lactate and pyruvate as evidence of increased

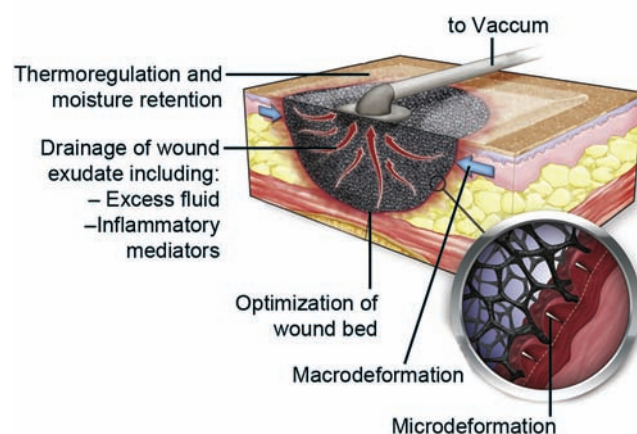


Fig. 1: Primary mechanisms of microdeformation in NPWT<sup>38</sup>



oxidative phosphorylation and thus energy production. The researchers found a 30% increase in levels of cytochrome *c* and ATP/adenosine diphosphate (54–441%) as compared with the control (gauze under suction and static controls). They also assessed protein synthesis as an indicator of increased energy production, discovering that platelet-derived growth factor and transforming growth factor beta were significantly greater than the controls. These changes in cell morphology created by NPWT ultimately increase a cell's ability to respond to mitogenic factors and promote cellular proliferation.<sup>14,15,18</sup>

### Foam Mechanics

The range of pore size on the foam, 400–600  $\mu\text{m}$ , is ideal to maximize the growth of tissue.<sup>19,20</sup> The pores in the foam material are constructed in a manner to produce compression where there is tissue contact with the foam and tension in between these areas of contact, thus producing mechanical strain that encourages cellular signaling to increase ECM production<sup>21</sup> (Figs 2A to D). A study of cell fibroblasts has shown their shape to be dendritic in unstretched tissue and flat “sheet like” in stretched tissue.<sup>22</sup> Further studies have directly correlated

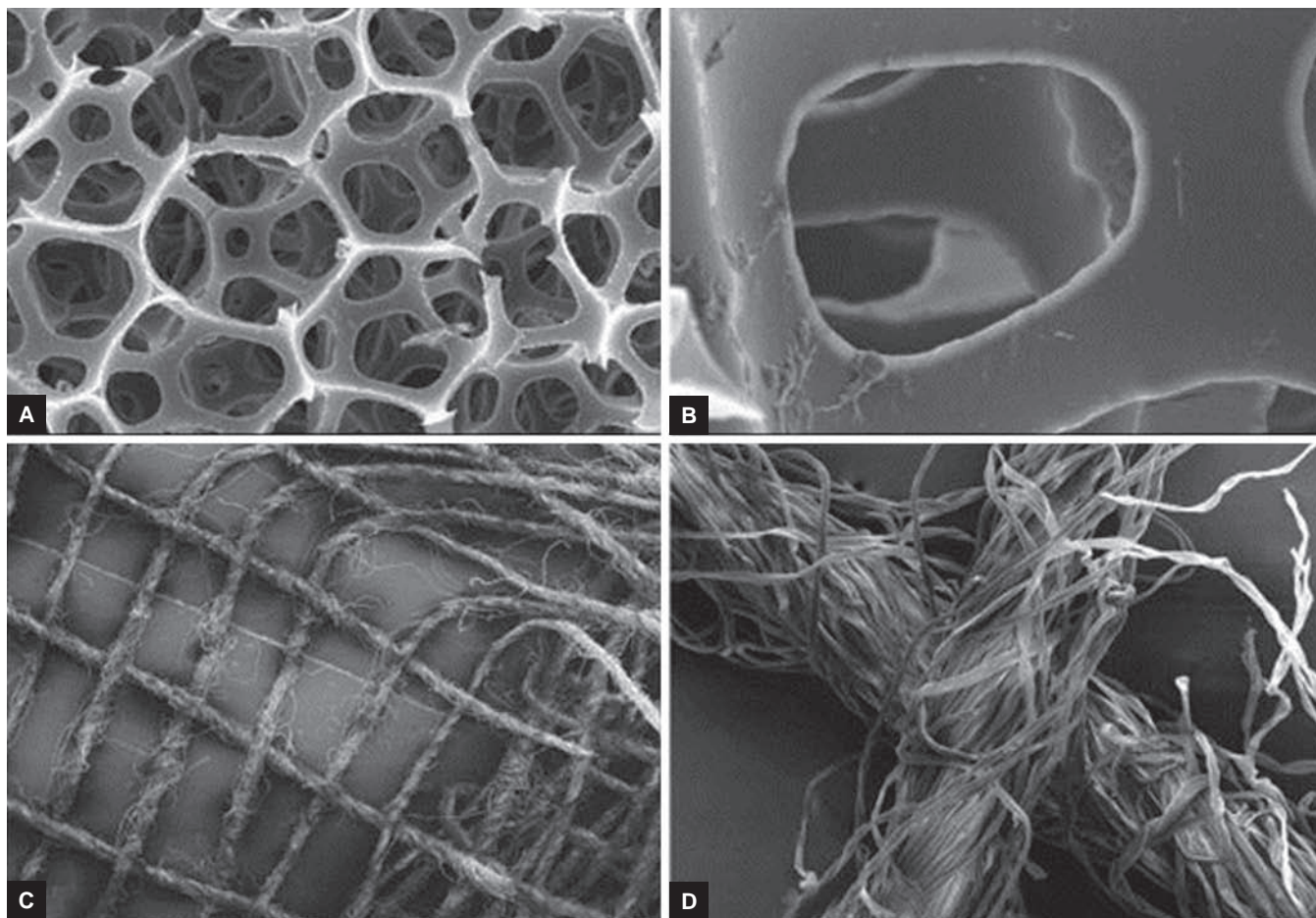
cell shape with activity: The dendritic shape correlates with a cell in resting state, while the flat shape to a cell undergoing stimulation or stress.<sup>23</sup>

The application of NPWT causes microdeformations in a wound, stretch of individual cells, and average increase in tissue strain ranging from 5 to 20%.<sup>24</sup> Furthermore, the use of this specialized foam with NPWT has been shown to increase the amount of microdeformation compared with gauze under pressure.<sup>21</sup>

## THERAPEUTIC EFFECTS

### Literature Review

The therapeutic effects of NPWT have been found to include quick healing of larger wounds, decreased surgical site infection, and reduced incidence of wound dehiscence.<sup>25–27</sup> A study from 2005 by Armstrong et al<sup>25</sup> compared the efficacy of NPWT in diabetic partial amputation wounds to published standards of moist wound care evaluating the University of Texas grade 2 or 3 wounds, which were much larger wounds than those previously studied (20.7  $\text{cm}^2$  vs 2.4–2.9  $\text{cm}^2$ ). The researchers found that utilizing NPWT for these more severe wounds was just as efficacious, if not more effective, than NPWT



**Figs 2A to D:** Micro-computerized tomographic scanning of VAC® GranuFoam® and gauze dressing (constructed from USP class VII gauze) demonstrates microscopic differences in structure and substance between the two dressing types

used on the shallower wounds in the prior studies. They also outlined that in their study, the non-NPWT patients demonstrated a fourfold higher risk of undergoing further amputation compared with those patients who used NPWT treatment. Such stark difference was attributed to accelerated wound healing and soft tissue deficit coverage with granulation tissue in the NPWT group.

It is likely that decreased amputation rate and increased rate of wound healing require a decreased bacterial burden. Many studies have illustrated the efficacy of NPWT in decreasing wound bacterial burden as well as incidence of infection. A meta-analysis by Semsarzadeh et al<sup>26</sup> examining 14 manuscripts utilizing NPWT and incidence of infection found the use of NPWT to decrease the rate of surgical site infections. Chadi et al<sup>28</sup> studied surgical site infection rates after sacral wound debridements in 49 patients. After adjusting for confounding factors, incisional NPWT was found to be an independent predictor in the prevention of a surgical site infection. Vargo<sup>29</sup> looked at data from NPWT used on patients with skin flaps with negative pressure applied for an average of 5.6 days, (5–7 days). None of the patients developed ischemia or necrosis of the skin flaps and no wound infections were identified. The overall wound complication rate was 3%, with a comparable historical control wound complication rate of 20%. They reported a statistically significant decrease in the infection rate with NPWT.

In addition to preventing surgical site infection, NPWT may be used to prevent wound dehiscence. Adogwa et al<sup>27</sup> gathered data on 160 patients in which long-segment thoracolumbar spine fusions were performed. Compared with the non-NPWT cohort, a 50% decrease in the incidence of wound dehiscence was observed with the use of NPWT.

Data from Liu et al<sup>30</sup> indicate that NPWT inhibits the invasion and proliferation of *Pseudomonas aeruginosa* in burn wounds and decreases early mortality in a murine model of burn-wound sepsis. These therapeutic benefits likely result from the ability of NPWT to decrease bacterial proliferation on the wound surface, reduce cytokine serum concentrations, and prevent damage to internal organs. In another study investigating *P. aeruginosa* bacterial burden in wounds created on goats, NPWT found significantly fewer bacteria in both NPWT groups when compared with traditional wet-to-dry dressings at all imaging sessions after the initial debridement and irrigation.<sup>31</sup> Negative pressure wound therapy may ultimately be used as a strategy to decrease the risk and protect various wounds from *P. aeruginosa* colonization and infection.

### Tissue Approximation and Support

Negative pressure wound therapy has also been utilized to aid in decreasing the incidence of hematoma and seroma

formation when placed over a closed incision.<sup>32</sup> Skin grafts are often used to assist in soft tissue coverage of wounds and are prone to failure due to increased shear forces, infection, or hematoma or seroma formation at the graft-recipient interface. Moisisidis et al<sup>33</sup> compared the quantitative incorporation and qualitative appearance of skin graft with the use of NPWT vs bolster dressing. The study found that the qualitative appearance of the skin graft recipient site was significantly improved in the NPWT group, while the quantitative incorporation between the two groups was not statistically significant. Scherer et al<sup>9</sup> found that skin grafts secured with NPWT had a decreased chance of necessitating repeat skin graft placement compared with standard bolster dressings, thus demonstrating its utility in skin graft incorporation and survival.

### Removing Exudates

While cytokines are a typically important driving force in healing, the increased presence of certain cellular signals is detrimental to a wound environment and may actually lead to stalling the wound healing process. Exudates from nonhealing wounds frequently exhibit elevated amounts of proinflammatory cytokines, such as tumor necrosis factor alpha (TNF- $\alpha$ ), interleukin (IL)-1 and IL-6, as well as increased amounts of matrix metalloproteinase (MMP-2 and MMP-9).<sup>34,35</sup> A study by Fajardo et al<sup>36</sup> showed that low concentrations of mouse recombinant TNF- $\alpha$  promoted angiogenesis, whereas high levels inhibited angiogenesis. Borgquist et al<sup>37</sup> studied the effect of NPWT on wound contracture and fluid removal in wounds created on eight pigs at varying levels of pressure. The study found the amount of fluid removed increased as the VAC pressure settings were increased, with the maximal amount of fluid removed at 125 mm Hg of subatmospheric pressure. A wound VAC will typically be set for 125 mm Hg of subatmospheric pressure of suction. It is important to note that a lower pressure setting can still be effective in the reduction of both exudate and wound size. Lower pressures may be of benefit in reducing pain attributed to NPWT.

### Promoting Angiogenesis

The promotion of angiogenesis is another of the many healing mechanisms provided by NPWT.<sup>38</sup> A suction pressure of 125 mm Hg has shown to increase blood flow to subcutaneous tissue and muscle to levels four times that of baseline.<sup>39</sup> Hypoxia-inducible factor-1 $\alpha$ -vascular endothelial growth factor pathway has been suggested to be a possible mechanism for NPWT-induced angiogenesis, and it is thought that a temporary reduction of blood flow to the wound with subsequent dramatic increase via prolonged NPWT may stimulate this pathway and ultimately lead to increased angiogenesis.<sup>40,41</sup>



## NEGATIVE PRESSURE WOUND THERAPY SOCIAL AND ECONOMIC IMPACT

### Social Factors

A wound of increased severity may require a higher frequency of dressing changes to ensure the maintenance of a robust healing environment. Proper dressing changes also often require access to skilled and trained individuals. Negative pressure wound therapy can serve to assist in reducing the frequency and number of dressing changes, along with the time in between each debridement.<sup>42</sup> This advantage can aid in patient transition from hospital care to an inpatient skilled nursing facility, inpatient rehabilitation, or home.

It is important to consider that a skilled nursing facility is often required for a smooth patient transition between the hospital and home setting. The facility nursing staff has the ability to perform VAC changes, ensure proper continued operation of the machine, as well as provide education and support to the patient in line with the goal of wound healing. Negative pressure wound therapy can be used as an effective tool to progress a wound to healing, while allowing a patient the possibility of decreased visits to a wound care center and physician provider.

### Economic Factors

Dealing with chronic diabetic wounds can be very expensive. Costs can quickly increase with dressing changes, hospital stays, and outpatient visits. Apleqvist et al<sup>43</sup> studied the economic factors posed against 162 diabetic patients with postamputation wounds. Patients were followed for 16 weeks and divided into two treatment groups. In this study, 77 patients received VAC therapy, while 85 were treated with traditional MWT. The study reported no difference in hospital admission numbers or length of stay. More surgical procedures and outpatient visits were found to be required by the MWT group compared with the VAC therapy group. Furthermore, cost of treatment was increased in the MWT compared with the VAC therapy group, with MWT costing almost \$39,000, while VAC therapy showed a lower cost at nearly \$26,000. Initially, VAC therapy may appear to be more expensive than MWT; however, the possibility of achieving wound healing at a faster rate may actually save individuals and institutions money throughout the course of treatment.

## ADDITIONAL NPWT TREATMENTS

### Ultraportable NPWT

In the first comparative-effectiveness study in tissue repair and wound healing, Armstrong et al<sup>44</sup> compared the ultraportable and mechanically powered smart negative pressure (SNaP) wound care system to the standard

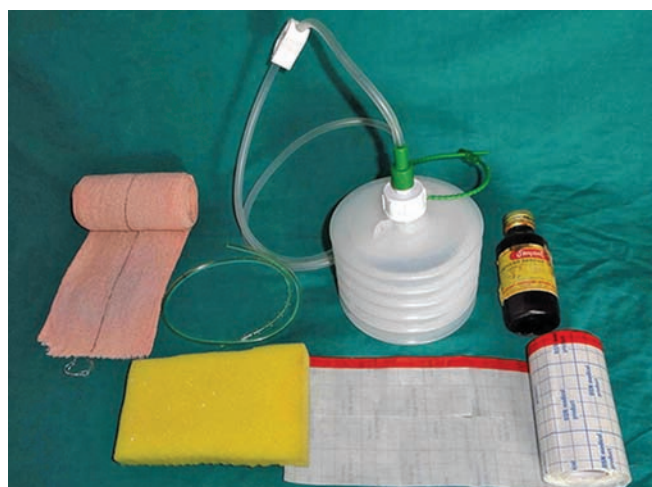electrically powered wound VAC therapy system in regard to treatment of lower extremity wounds. The study randomized 132 patients with lower extremity wounds less than 100 cm<sup>2</sup> into receiving treatment with either system and found no significant difference in the amount of wound size reduction or wound closure between the two devices. They did report that the SNaP system was able to be applied more rapidly and, likely due to the SNaP system's small size, it had less apparent impact on patients' daily activities. The authors concluded that mechanically powered ultraportable devices, such as SNaP can be a valuable tool in patients with smaller wounds that desire less impact on daily activities.

### Bellows-type and "Locally Sourced" NPWT for Low-resource Regions

Mody et al<sup>45</sup> in 2015 described the use of a bellow pump to provide hand-generated negative pressure therapy for patients in resource-constrained areas. The pump is able to provide approximately 75 mm Hg of vacuum pressure and also serves as a receptacle for wound exudates. The study analyzed the device on 71 dressings, with subset analysis of the final dressing finding that negative pressure was maintained for a period of approximately 32 hours. Other authors have reported the use of basic medical supplies to fabricate similar devices with beneficial outcomes<sup>46</sup> (Fig. 3). Remarkably, these types of devices have been shown to provide effective NPWT to patients throughout the world who would typically not have access to equipment with a higher resource and economical cost.

### Antimicrobial Foam

Negative pressure wound therapy may also be used as a strategy to decrease or protect an open wound from infection. Animal studies have found a decreased incidence of



**Fig. 3:** Saraiya and Shah<sup>46</sup> utilized available medical supplies to recreate NPWT in areas of low resource and socioeconomic status

*P. aeruginosa* with NPWT application to wounds created on goats and mice.<sup>30,31</sup> Specialized foam applications can also assist in decreasing wound bacterial burden. Özgür et al<sup>47</sup> divided 21 patients with wounds into two groups, with 10 receiving traditional GranuFoam dressings, while the other 11 received silver-coated GranuFoam dressing. The study found that patients who received silver-coated dressing had an increased number of negative wound cultures compared with traditional foam dressing. Siegel et al<sup>48</sup> also demonstrated the use of silver-coated foam in decreasing the length of hospital stay and frequency of surgical debridement in patients with pelvic and extremity wounds.

### Instillation

The application of NPWT with instillation (NPWTi) allows the delivery of practitioner-selected fluid to the wound with VAC therapy occurring between cycles of instillation, with the ultimate goal being decreased wound bacterial burden. Various instillation solutions have been described, with consensus guidelines deeming polyhexanide, polyhexanide plus betadine, and Microcyn/Dermacyn as just a few of the possible options.<sup>49</sup> Instillation of doxycycline and other tetracycline antibiotics has been shown to inhibit excess MMP production to create an environment that will allow for improved wound healing.<sup>50</sup> In a small study, surgical debridement followed by NPWTi with Dakin's solution (dilute sodium hypochlorite) application for a period of 10 days showed no growth of bacteria in five patients who previously were colonized with greater than 10<sup>5</sup> bacteria.<sup>51</sup> Other authors have also reported on the use of Dakin's through NPWTi.<sup>52</sup> Several studies, including a single randomized, double-blinded, placebo-controlled trial, demonstrated efficacy of topical and injected insulin through NPWTi directly to ulcers in accelerating wound healing.<sup>53,54</sup> Scimeca et al<sup>50</sup> presented a patient who was switched to NPWTi with insulin from traditional NPWT after the wound showed apparent bacterial colonization with biofilm and increased amounts of periwound maceration on traditional NPWT treatments. After 48 hours of therapy, the authors related the change from a wound with the prior description to a wound with 90% granular base and minimal periwound maceration, ultimately allowing the patient to progress to skin graft application.

### Topical Application of Collagenase

Miller et al<sup>55</sup> studied the use of collagenase ointment on diabetic wounds in conjunction with the use of NPWT for enzymatic debridement. Utilizing clostridium collagenase allows for the destruction and easy removal of nonviable fibrous tissue while healthy viable tissue

remains intact. Clostridium collagenase therapy in combination with NPWT in this case report was proven to be a beneficial combination in complicated wound cases.

### CONTRAINDICATIONS TO NPWT

The Food and Drug Administration reports that NPWT is contraindicated for the following wound types and conditions: Necrotic tissue with eschar present, untreated osteomyelitis, nonenteric and unexplored fistulas, malignancy in the wound and exposed vasculature, nerves, organs, or anastomotic sites. Additional risk factors to consider include patients who have a high-risk for bleeding or hemorrhage, and patients on anticoagulants or platelet aggregation inhibitor.<sup>56</sup> It is important for the physician to evaluate not only the wound but the patient as a whole prior to administration of NPWT.

### CONCLUSION

Treatment options and therapeutic approaches in wound care are vast and diverse. These include well-known treatments ranging from simple saline-moistened gauze and topical wound gels, to more complex enzymatic debridement topicals and antimicrobial colloidal dressings. Negative pressure wound therapy is a significant advancement in the realm of biomedical and wound healing technology, which harnesses the innate physiologic cellular response to external stimuli to promote molecular change, incite cellular proliferation, and advance wound healing. The coupling of this biological response to NPWT with further biomedical advances has allowed NPWT to emerge as arguably one of the most powerful tools to assist in wound healing known to date. As improvements in technique and application are continuously being developed and addressed throughout the literature, it is important for one to determine the benefit from the application of NPWT; undoubtedly, it has the potential to serve as an effective method to accelerate the rate of wound closure and improve a patient's outcome.

### REFERENCES

1. Abdelaal MAZ, Giovenco NA, Slepian MJ, Armstrong DG. Tissue repair and wound healing: a trip back to the future. In: Technological advances in surgery, trauma and critical care. New York, NY: Springer; 2015. p. 563-571.
2. Mouës CM, Heule F, Legerstee R, Hovius SE. Five millennia of wound care products – what is new? A literature review. *Ostomy Wound Manage* 2009 Mar;55(3):16-18, 20, 22 passim.
3. Lambert KV, Hayes P, McCarthy M. Vacuum assisted closure: a review of development and current applications. *Eur J Vasc Endovasc Surg* 2005 Mar;29(3):219-226.
4. Ozer MT, Coskun AK, Ozerhan IH, Ersoz N, Yildiz R, Sinan H, Demirbas S, Kozak O, Uzar AI, Cetiner S. Use of vacuum-assisted closure (VAC<sup>TM</sup>) in high-energy complicated perineal injuries: analysis of nine cases. *Int Wound J* 2011 Dec;8(6):599-607.

5. Schlatterer D, Hirshorn K. Negative pressure wound therapy with reticulated open cell foam-adjunctive treatment in the management of traumatic wounds of the leg: a review of the literature. *J Orthop Trauma* 2008 Nov-Dec;22(10 Suppl): S152-S160.
6. Nicolaides AN, Cardiovascular Disease Educational and Research Trust, European Society of Vascular Surgery. The International Angiology Scientific Activity Congress Organization, International Union of Angiology, Union Internationale de Phlebologie at the Abbaye des Vaux de Cernay. Investigation of chronic venous insufficiency: a consensus statement (France, March 5–9, 1997). *Circulation* 2000 Nov 14;102(20):E126-E163.
7. Smith PDC. The management of chronic venous disorders of the leg: an evidence-based report of an international task force. *Phlebology* 1999;14 (Suppl 1):35-42.
8. Vuerstaek JD, Tryfon V, Jan W, Patty N, Neumann MH, Veraart JC. State-of-the-art treatment of chronic leg ulcers: a randomized controlled trial comparing vacuum-assisted closure (V.A.C.) with modern wound dressings. *J Vasc Surg* 2006 Nov;44(5):1029-1037.
9. Scherer LA, Shiver S, Chang M, Meredith JW, Owings JT. The vacuum assisted closure device: a method of securing skin grafts and improving graft survival. *Arch Surg* 2002 Aug;137(8):930-933; discussion 933-934.
10. Blume PA, Walters J, Payne W, Ayala J, Lantis J. Comparison of negative pressure wound therapy using vacuum-assisted closure with advanced moist wound therapy in the treatment of diabetic foot ulcers: a multicenter randomized controlled trial. *Diabetes Care* 2008 Apr;31(4):631-636.
11. Armstrong DG, Wrobel J, Robbins JM. Guest Editorial: are diabetes-related wounds and amputations worse than cancer? *Int Wound J* 2007 Dec;4(4):286-287.
12. Lessing C, Slack P, Hong KZ, Kilpadi D, McNulty A. Negative pressure wound therapy with controlled saline instillation (NPWTi): dressing properties and granulation response *in vivo*. *Wounds* 2011 Oct;23(10):309-319.
13. McNulty AK, Marisa S, Teri F, Patricia V, Kris K. Effects of negative pressure wound therapy on cellular energetics in fibroblasts grown in a provisional wound (fibrin) matrix. *Wound Repair Regen* 2009 Mar-Apr;17(2):192-199.
14. Chen CS. Geometric control of cell life and death. *Science* 1997 May 30;276(5317):1425-1428.
15. Huang S, Chen CS, Ingber DE. Control of cyclin D1, p27(Kip1), and cell cycle progression in human capillary endothelial cells by cell shape and cytoskeletal tension. *Mol Biol Cell* 1998 Nov;9(11):3179-3193.
16. McNulty AK, Schmidt M, Feeley T, Kieswetter K. Effects of negative pressure wound therapy on fibroblast viability, chemotactic signaling, and proliferation in a provisional wound (fibrin) matrix. *Wound Repair Regen* 2007 Nov-Dec;15(6): 838-846.
17. Furuya K, Sokabe M, Furuya S. Characteristics of subepithelial fibroblasts as a mechano-sensor in the intestine: cell-shape-dependent ATP release and P2Y1 signaling. *J Cell Sci* 2005 Aug 1;118(Pt 15):3289-3304.
18. Ingber DE, Prusty D, Sun Z, Betensky H, Wang N. Cell shape, cytoskeletal mechanics, and cell cycle control in angiogenesis. *J Biomech* 1995 Dec;28(12):1471-1484.
19. Wake MC, Patrick CW Jr, Mikos AG. Pore morphology effects on the fibrovascular tissue growth in porous polymer substrates. *Cell Transplant* 1994 Jul-Aug;3(4):339-343.
20. Taylor DF, Smith FB. Porous methyl methacrylate as an implant material. *J Biomed Mater Res* 1972;6(1):467-479.
21. Wilkes R, Zhao Y, Kieswetter K, Haridas B. Effects of dressing type on 3D tissue microdeformations during negative pressure wound therapy: a computational study. *J Biomech Eng* 2009 Mar;131(3):031012.
22. Langevin HM, Bouffard NA, Badger GJ, Iatridis JC, Howe AK. Dynamic fibroblast cytoskeletal response to subcutaneous tissue stretch *ex vivo* and *in vivo*. *Am J Physiol Cell Physiol* 2005 Mar;288(3):C747-C756.
23. Grinnell F, Ho C-H, Tamariz E, Lee DJ, Skuta G. Dendritic fibroblasts in three-dimensional collagen matrices. *Mol Biol Cell* 2003 Feb;14(2):384-395.
24. Saxena V, Hwang CW, Huang S, Eichbaum Q, Ingber D, Orgill DP. Vacuum-assisted closure: microdeformations of wounds and cell proliferation. *Plast Reconstr Surg* 2004 Oct;114(5):1086-1096.
25. Armstrong DG, Lavery LA, Diabetic Foot Study Consortium. Negative pressure wound therapy after partial diabetic foot amputation: a multicentre, randomised controlled trial. *Lancet* 2005 Nov 12;366(9498):1704-1710.
26. Semsarzadeh NN, Tadisina KK, Maddox J, Chopra K, Singh DP. Closed incision negative-pressure therapy is associated with decreased surgical-site infections: a meta-analysis. *Plast Reconstr Surg* 2015 Sep;136(3):592-602.
27. Adogwa O, Fatemi P, Perez E, Moreno J, Gazcon GC, Gokaslan ZL, Cheng J, Gottfried O, Bagley CA. Negative pressure wound therapy reduces incidence of postoperative wound infection and dehiscence after long-segment thoracolumbar spinal fusion: a single institutional experience. *Spine J* 2014 Dec 1;14(12):2911-2917.
28. Chadi SA, Kidane B, Britto K, Brackstone M, Ott MC. Incisional negative pressure wound therapy decreases the frequency of postoperative perineal surgical site infections: a cohort study. *Dis Colon Rectum* 2014 Aug;57(8):999-1006.
29. Vargo D. Negative pressure wound therapy in the prevention of wound infection in high risk abdominal wound closures. *Am J Surg* 2012 Dec;204(6):1021-1023; discussion 1023-1024.
30. Liu Y, Zhou Q, Wang Y, Liu Z, Dong M, Wang Y, Li X, Hu D. Negative pressure wound therapy decreases mortality in a murine model of burn-wound sepsis involving *Pseudomonas aeruginosa* infection. *PLoS One* 2014 Feb 28;9(2):e90494.
31. Lalliss SJ, Stinner DJ, Waterman SM, Branstetter JG, Masini BD, Wenke JC. Negative pressure wound therapy reduces pseudomonas wound contamination more than *Staphylococcus aureus*. *J Orthop Trauma* 2010 Sep;24(9):598-602.
32. Kilpadi DV, Cunningham MR. Evaluation of closed incision management with negative pressure wound therapy (CIM): hematoma/seroma and involvement of the lymphatic system. *Wound Repair Regen* 2011 Sep-Oct;19(5):588-596.
33. Moisidis E, Heath T, Boorer C, Ho K, Deva AK. A prospective, blinded, randomized, controlled clinical trial of topical negative pressure use in skin grafting. *Plast Reconstr Surg* 2004 Sep 15;114(4):917-922.
34. Trengove NJ, Bielefeldt-Ohmann H, Stacey MC. Mitogenic activity and cytokine levels in non-healing and healing chronic leg ulcers. *Wound Repair Regen* 2000 Jan-Feb;8(1): 13-25.
35. Wysocki AB, Staiano-Coico L, Grinnell F. Wound fluid from chronic leg ulcers contains elevated levels of metalloproteinases MMP-2 and MMP-9. *J Invest Dermatol* 1993 Jul;101(1): 64-68.



36. Fajardo LE, Kwan HH, Kowalski J, Prionas SD, Allison AC. Dual role of tumor necrosis factor- $\alpha$  in angiogenesis. *Am J Pathol* 1992 Mar;140(3):539-544.
37. Borgquist O, Ingemansson R, Malmjö M. The influence of low and high pressure levels during negative-pressure wound therapy on wound contraction and fluid evacuation. *Plast Reconstr Surg* 2011 Feb;127(2):551-559.
38. Huang C, Leavitt T, Bayer LR, Orgill DP. Effect of negative pressure wound therapy on wound healing. *Curr Probl Surg* 2014 Jul;51(7):301-331.
39. Morykwas MJ, Argenta LC, Shelton-Brown EI, McGuirt W. Vacuum-assisted closure: a new method for wound control and treatment: animal studies and basic foundation. *Ann Plast Surg* 1997 Jun;38(6):553-562.
40. Kairinos N, Solomons M, Hudson DA. The paradox of negative pressure wound therapy – *in vitro* studies. *J Plast Reconstr Aesthet Surg* 2010 Jan;63(1):174-179.
41. Wackenfors A, Sjögren J, Gustafsson R, Algotsson L, Ingemansson R, Malmjö M. Effects of vacuum-assisted closure therapy on inguinal wound edge microvascular blood flow. *Wound Repair Regen* 2004 Nov-Dec;12(6):600-606.
42. Wu SC, Armstrong DG. Clinical outcome of diabetic foot ulcers treated with negative pressure wound therapy and the transition from acute care to home care. *Int Wound J* 2008 Jun;5(Suppl 2):10-16.
43. Apleqvist J, Armstrong DG, Lavery LA. Resource utilization and economic costs of care based on a randomized trial of vacuum-assisted closure therapy in the treatment of diabetic foot wounds. *J Vasc Surg* 2008 Sep;48(3):770.
44. Armstrong DG, Marston WA, Reyzelman AM, Kirsner RS. Comparative effectiveness of mechanically and electrically powered negative pressure wound therapy devices: a multicenter randomized controlled trial. *Wound Repair Regen* 2012 May-Jun;20(3):332-341.
45. Mody GN, Zurovcik DR, Joharifard S, Kansayisa G, Uwimana G, Baganizi E, Ntakiyiruta G, Mugenzi D, Riviello R. Biomechanical and safety testing of a simplified negative-pressure wound therapy device. *Plast Reconstr Surg* 2015 Apr;135(4):1140-1146.
46. Saraiya HA, Shah MN. Use of indigenously made negative-pressure wound therapy system for patients with diabetic foot. *Adv Skin Wound Care* 2013 Feb;26(2):74-77.
47. Özgür G, Umut T, Aydın T, Sener B, Naci K. The use of vacuum-assisted closure and GranuFoam Silver® dressing in the management of diabetic foot ulcer. *Surg Infect* 2015 Oct;16(5):558-565.
48. Siegel HJ, Herrera DF, Gay J. Silver negative pressure dressing with vacuum-assisted closure of massive pelvic and extremity wounds. *Clin Orthop Relat Res* 2014 Mar;472(3):830-835.
49. Kim PJ, Attinger CE, Steinberg JS, Evans KK, Lehner B, Willy C, Lavery L, Wolvos T, Orgill D, Ennis W, et al. Negative-pressure wound therapy with instillation: international consensus guidelines. *Plast Reconstr Surg* 2013 Dec;132(6):1569-1579.
50. Scimeca CL, Bharara M, Fisher TK, Giovenco N, Armstrong DG. Novel use of doxycycline in continuous-instillation negative pressure wound therapy as “wound chemotherapy.” *Foot Ankle Spec* 2010 Aug;3(4):190-193.
51. Raad W, Lantis JC 2nd, Tyrie L, Gendics C, Todd G. Vacuum-assisted closure instill as a method of sterilizing massive venous stasis wounds prior to split thickness skin graft placement. *Int Wound J* 2010 Apr;7(2):81-85.
52. Giovenco NA, Bui TD, Fisher T, Mills JL, Armstrong DG. Wound chemotherapy by the use of negative pressure wound therapy and infusion. *Eplasty* 2010 Jan 8;10:e9.
53. Zhang X-J, Wu X, Wolf SE, Hawkins HK, Chinkes DL, Wolfe RR. Local insulin-zinc injection accelerates skin donor site wound healing. *J Surg Res* 2007 Sep;142(1):90-96.
54. Wilson JM, Baines R, Babu ED, Kelley CJ. A role for topical insulin in the management problematic surgical wounds. *Ann R Coll Surg Engl* 2008 Mar;90(2):160.
55. Miller JD, Carter E, Hatch DC, Zhubrak M, Giovenco NA, Armstrong DG. Use of collagenase ointment in conjunction with negative pressure wound therapy in the care of diabetic wounds: a case series of six patients. *Diabet Foot Ankle* 2015 Jan 27;6:24999.
56. US Food and Drug Administration. FDA safety communication: UPDATE on serious complications associated with negative pressure wound therapy systems; 2011.