

CASE REPORT

A Rare Case of Primary Synovial Chondromatosis of the Ankle

¹Viswanathan Chathoth, ²Sriram Sankaranarayanan

ABSTRACT

Synovial chondromatosis is a condition where the synovial lining of joints, tendons, or bursa undergoes metaplasia into cartilaginous loose bodies. Primary synovial chondromatosis of the ankle joint is very rare and less commonly reported in literature. We report a case of primary synovial chondromatosis of the ankle that we encountered in our clinic. A 33-year-old male patient presented with a history of multiple swellings around his right ankle joint, along with dull aching pain. Both the clinical examination and X-rays were suggestive of primary synovial chondromatosis of the ankle. We performed an open loose body removal and synovectomy of the ankle. Histopathology confirmed the diagnosis of primary synovial chondromatosis. We report this case owing to its rarity of presentation.

Keywords: Ankle, Loose body removal and synovectomy, Synovial chondromatosis.

How to cite this article: Chathoth V, Sankaranarayanan S. A Rare Case of Primary Synovial Chondromatosis of the Ankle. *J Foot Ankle Surg (Asia-Pacific)* 2016;3(1):53-55.

Source of support: Nil

Conflict of interest: None

INTRODUCTION

Synovial chondromatosis is a benign condition where the synovium of the joint, tendon, or bursa undergoes metaplasia into cartilage. The disease manifests itself as multiple loose bodies around the joint. Symptoms of the disease may include swelling, pain, locking, or stiffness.^{1,2} Synovial chondromatosis, if left untreated, has a potential for progressing to end-stage arthritis. There have also been reports in literature of transformation into chondrosarcoma in patients with untreated synovial chondromatosis.³ Primary synovial chondromatosis of the ankle joint is a rare condition, and it has been less commonly reported in literature.

CASE PRESENTATION

A 33-year-old male patient who was a construction worker by profession presented with swelling in his right ankle, which had been lasting for over 5 years. His job involved standing for long hours. He reported a dull aching pain on his right ankle after long hours of standing. He had no other mechanical symptoms, restriction of ankle movement, or locking of the ankle. On physical examination, his right ankle revealed multiple palpable loose bodies. There was no tenderness around the ankle joint. Range of movement including dorsiflexion, plantar flexion, inversion, and eversion was full and comparable with the opposite side. Skin around the ankle was normal. His other joints were clinically normal. Digital X-rays with anteroposterior and lateral views of his right ankle were taken. X-rays revealed multiple radiopaque loose bodies around the ankle (Figs 1 and 2).

A diagnosis of primary synovial chondromatosis was made. Owing to the extensive nature of the synovial chondromatosis in this patient, an open approach using two ankle incisions (anteromedial and anterolateral) was preferred over arthroscopic removal. The entire ankle joint including the posterior pouch of the ankle was accessible through these two incisions. A thorough loose body removal and synovectomy were performed (Fig. 3). The loose bodies that were extracted had a pale white color, and they were bony hard in consistency (Fig. 4).

The specimen was sent for histopathological examination; the diagnosis confirmed synovial chondromatosis.

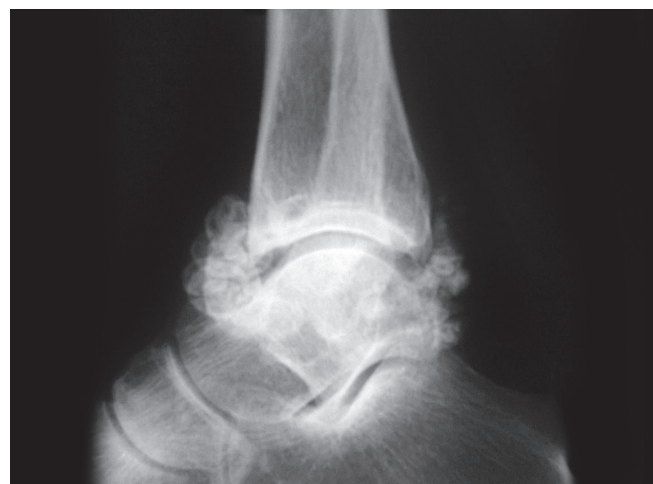


Fig. 1: Pre-op X-ray lateral view

¹Consultant, ²Clinical Fellow

¹Department of Orthopedics, Valluvanad Hospital, Ottapalam Kerala, India

²Orthopedic Sports Medicine and Arthroscopy, Langhorne Pennsylvania, USA

Corresponding Author: Sriram Sankaranarayanan, Clinical Fellow, Orthopedic Sports Medicine and Arthroscopy Aria 3B Hospitals, 380 N Oxford Valley Road, Langhorne, Pennsylvania USA, Phone: 3479094023, e-mail: sriram1812@gmail.com

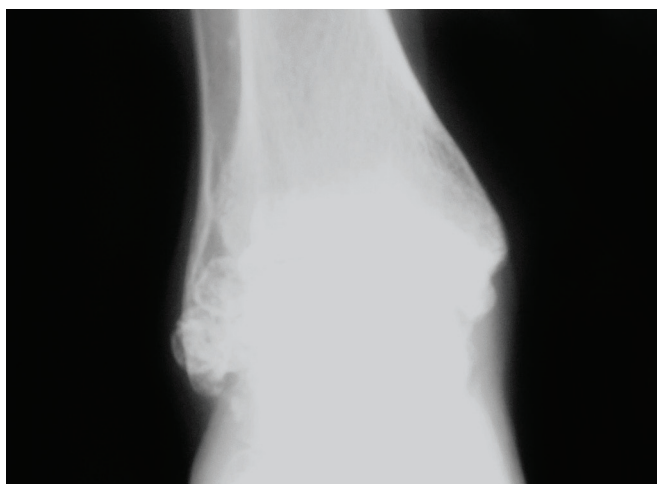


Fig. 2: Pre-op X-ray anteroposterior view

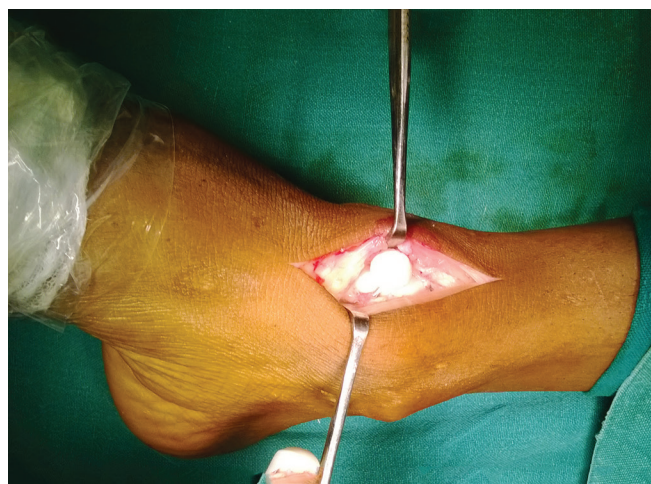

Fig. 3: Intraoperative photo

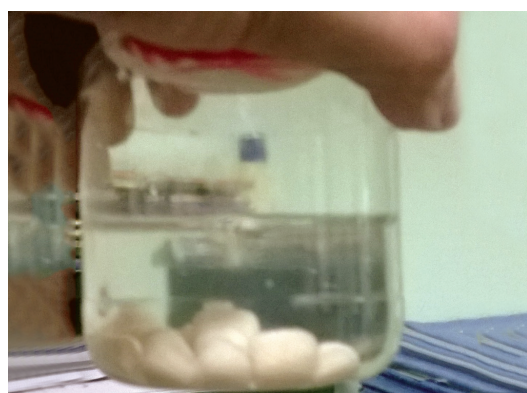

Fig. 4: Loose bodies removed

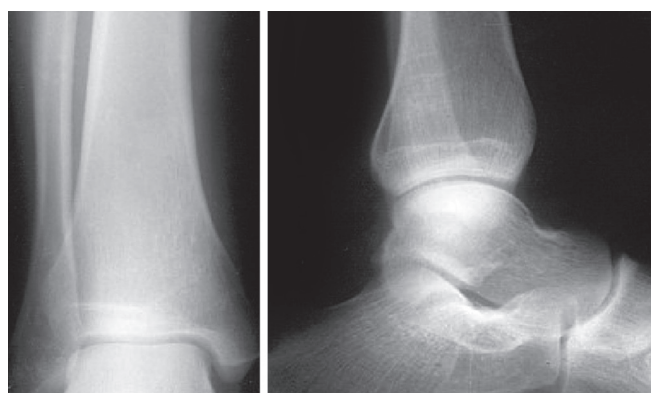


Fig. 5: One year follow-up X-ray

Following surgery, physiotherapy was initiated immediately. The patient was followed up for a checkup and dressing on day 5 and suture removal on day 12. The patient had an uneventful recovery. In the final follow-up, 1 year following surgery, the patient was pain free and asymptomatic. An X-ray taken at 1-year follow-up did not show any signs of recurrence (Fig. 5).

LITERATURE REVIEW AND DISCUSSION

Synovial chondromatosis is a condition where the synovial lining of joints, tendon, or bursa undergoes metaplastic change. This results in the formation of multiple cartilaginous loose bodies in the joint. Milgram¹ categorized the disease progress into three stages:

1. *Early:* No loose bodies but active synovial disease
2. *Transitional:* Active synovial disease and loose bodies
3. *Late:* Loose bodies but no synovial disease.

The disease is seen mainly in patients between 20 and 40 years of age, with males being more commonly affected. Symptoms include pain, mechanical symptoms, stiffness, restriction of range of movement, and locking. The knee joint is the most commonly affected joint followed by the elbow, shoulder, and hip joints.²

Synovial chondromatosis of the ankle *per se* is an exceedingly rare entity with very few reports in literature. Pathak et al⁴ in 2006, Shearer et al⁵ in 2007, Ozyurek et al⁶ in 2013, and Ozmeric et al⁷ in 2014 have reported isolated cases of synovial chondromatosis of the ankle treated with either open or arthroscopic excision. In the largest reported series of patients with foot and ankle synovial chondromatosis by Galat et al⁸ in 2008, eight patients underwent synovectomy and excision for the condition. In an average follow-up period of 9.5 years, four of these patients had an uneventful recovery following surgery. However, one patient underwent excision and midfoot arthrodesis for severe midfoot destruction due to degenerative changes and three patients underwent below knee amputation, one for multiple recurrences and two for malignant transformation to low-grade chondrosarcoma. In a clinicopathologic review of 53 cases of primary synovial chondromatosis covering a period of 30 years, Davis et al³ found that the condition was always monarticular, the most common site being the knee joint (70%) followed by the hip (20%). In this series, the ankle joint involvement was rare (<10%). Degenerative joint disease was demonstrated in three patients (5%), all occurring in the hip joint. Nine patients suffered recurrences

(15%), and three patients (5%) underwent malignant change. These reports demonstrate that synovial chondromatosis of the ankle does have a potential for developing degenerative joint disease and malignant transformation, with a relative risk of transformation as high as 5%. Hence, the condition should not be neglected and it should ideally be treated with synovectomy and excision. The high rate of recurrence following surgery should also be borne in mind.

The differential diagnosis of primary synovial chondromatosis includes secondary reactive synovial chondromatosis and synovial chondrosarcoma. A diagnosis of synovial chondromatosis is made by physical examination and radiography. X-rays of the affected joints show multiple radiopaque loose bodies which can be either intra-articular or extra-articular. Magnetic resonance imaging is also an useful investigation. The treatment option includes either open or arthroscopic loose body removal and synovectomy along with histopathological confirmation.

CONCLUSION

Primary synovial chondromatosis of the ankle joint is a rare condition. We present this case report owing to its rarity and clinical significance.

REFERENCES

1. Milgram JW. Synovial osteochondromatosis: a histopathological study of thirty cases. *J Bone Joint Surg Am* 1977 Sep;59(6): 792-801.
2. Aguilera S, Pizzi T, Donoso I. Synovial chondromatosis: review of 25 monoarticular cases. *Rev Med Chil* 1995 Oct; 123(10):1257-1262.
3. Davis RI, Hamilton A, Biggart JD. Primary synovial chondromatosis: a clinicopathologic review and assessment of malignant potential. *Hum Pathol* 1998 Jul;29(7): 683-688.
4. Pathak S, Joseph C, Aravinda M, Sonar S, Vinodh K, Rajan D. A case of primary intra-articular and extra articular synovial chondromatosis of ankle and foot. *Int J Orthoped Surg* 2006;4(1).
5. Shearer H, Stern P, Brubacher A, Pringle T. A case report of bilateral synovial chondromatosis of the ankle. *Chiropr Osteopat* 2007 Nov;15:18.
6. Ozyurek S, Atik A, Sivrioglu AK, Ege T. Primary synovial osteochondromatosis of the ankle. *BMJ Case Rep* 2013; doi:10.1136/bcr-2013-009046
7. Ozmeric A, Aydogan NH, Kocadal O, Kara T, Pepe M, Gozel S. Arthroscopic treatment of synovial chondromatosis in the ankle joint. *Int J Surg Case Rep* 2014 Oct;5(12): 1010-1013.
8. Galat DD1, Ackerman DB, Spoon D, Turner NS, Shives TC. Synovial chondromatosis of the foot and ankle. *Foot Ankle Int* 2008 Mar;29(3):312-317.