

Proximal Medial Tibial Bone Graft Harvesting in Foot and Ankle Surgery

¹Rakesh Dalal, ²Hari Kovilazhikathu Sugathan, ³Rajesh Rachha

ABSTRACT

Cancellous bone graft harvesting from proximal tibia is usually by a lateral approach. We describe our technique and results in harvesting proximal tibia bone graft by a medial approach in foot and ankle surgery. Our results confirm that medial proximal tibial bone graft harvesting is a relatively safe and easy procedure to obtain adequate amount of autogenous cancellous bone graft. Donor site morbidity was found to be very low and fusion rate was found to be excellent in a variety of foot and ankle surgeries.

Keywords: Proximal medial tibia, Bone graft harvesting, Foot and ankle.

How to cite this article: Dalal R, Sugathan HK, Rachha R. Proximal Medial Tibial Bone Graft Harvesting in Foot and Ankle Surgery. *J Foot Ankle Surg (Asia-Pacific)* 2015;2(1):27-30.

Source of support: Nil

Conflict of interest: None

INTRODUCTION

Cancellous bone graft is needed in small and moderate amounts in many procedures in foot and ankle surgery. Such graft can be obtained from the Iliac crest, proximal tibia, distal tibia and calcaneum. Iliac crest graft is associated with significant donor site morbidity. Exposure is difficult for distal tibial graft harvest. Calcaneal graft is limited in quantity.¹ Synthetic bone graft substitutes and allografts have unproven efficacy and have obvious cost implications. Proximal tibial graft can be harvested either from the medial or lateral cortical surface. Medial tibial exposure is easier, quicker and involves virtually no soft tissue dissection. We present our surgical technique and

results of medial proximal tibial bone graft harvesting (MPTBGH).

SURGICAL TECHNIQUE

Cancellous bone graft was harvested from ipsilateral proximal tibia through medial approach. Patient supine, tibial tuberosity and anterior and posterior borders of medial surface marked. Skin incision is about 5 to 7 cm, along the midpoint of anterior and posterior borders as marked (Fig. 1). Periosteum is incised over a 6 × 5 cm area and reflected with a periosteum elevator. Drill holes are made at 1 cm intervals averaging 6 longitudinally and 4 to 5 horizontally to complete a rectangle (Fig. 2). The holes are joined together with a saw blade/osteotomes to raise a rectangular (Fig. 3), bevelled window of cortical bone and is lifted out and saved carefully (Fig. 4). Cancellous bone is then harvested from the medullary cavity using a curette and nibbler. Good quantity of graft is usually available from the metaphyseal bone (Fig. 5). Marrow is harvested into a syringe using a 'quill' (Fig. 6) and is injected into the recipient site to improve the osteogenic potential. The window is then repositioned (Fig. 7) and wound closed in two layers (Fig. 8). Patients weight bearing status was determined by the index procedure.

MATERIALS AND METHODS

We conducted a retrospective case series study of all the patients who underwent MPTBGH from 2005 to 2013. Data were collected from case records, electronic patient records and picture archiving and communicating system (PACS). A total of 50 consecutive patients who underwent the procedure were selected intraoperatively, quality of bone harvest and technical difficulties in harvesting were recorded.

Forty-five patients (46 procedures—Table 1) were available for telephone review. Postoperative pain, donor site morbidity and overall patient satisfaction were noted.

RESULTS

Mean age was 60.3 years (24–78 yrs). There were 32 males (71%) and 13 females (29%). All patients had ipsilateral proximal tibia bone graft. The mean duration of follow-up was 14 months (6–36 months).

¹Consultant and Senior Lecturer, ²Fellow

³Senior Clinical Fellow

^{1,2}Department of Foot and Ankle Surgery; Department of Trauma and Orthopedics, Stepping Hill Hospital, University of Manchester, Cheshire, United Kingdom

³Department of Hip and Knee Surgery; Department of Trauma and Orthopedics, Leicester General Hospital, Leicestershire United Kingdom

Corresponding Author: Rakesh Dalal, Consultant and Senior Lecturer, Department of Foot and Ankle Surgery; Department of Trauma and Orthopedics, Stepping Hill Hospital, University of Manchester, Cheshire, United Kingdom, Phone: 01614831010 e-mail: rdalal7119@aol.com

Intraoperative graft quantity was found to be excellent in all but one case (98%). We felt graft was not adequate in a 78 years old patient.

Thirty-six patients (80%) were pain-free at 6 weeks follow-up. Forty-four patients (96%) pain-free at 3 months. No patients complained of any significant prolonged pain at follow-up.

One patient had a slight uncomfortable numbness at the graft site. There was one fracture through the graft site due to slipping on ice 6 weeks post-surgery.

Patient satisfaction was found to be excellent at the final telephone review.

Forty-four patients (98%) were subjectively happy with the procedure and 43 patients (95.6%) were satisfied with the esthetic look of the scar. Forty patients (89%) said that they would recommend this procedure.

Union rate was 95.7% (44/46). Two patients who underwent revision first metatarsophalangeal joint (MTPJ) fusion had non-union requiring further revision procedures.

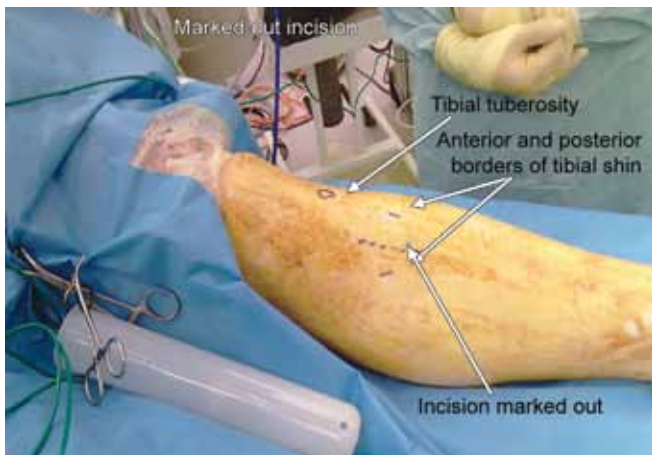


Fig. 1: Skin incision

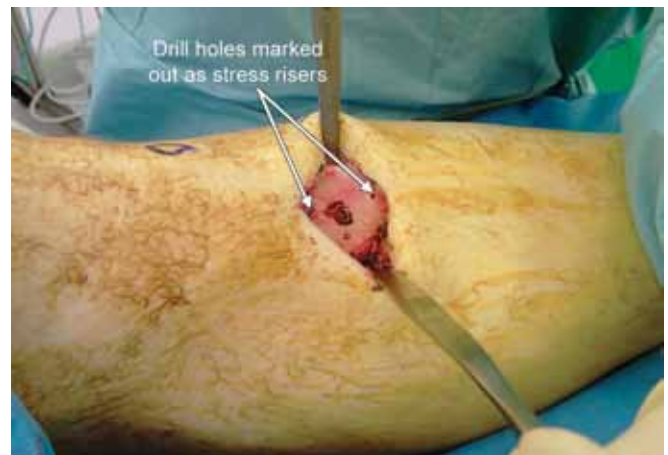


Fig. 2: Drill holes

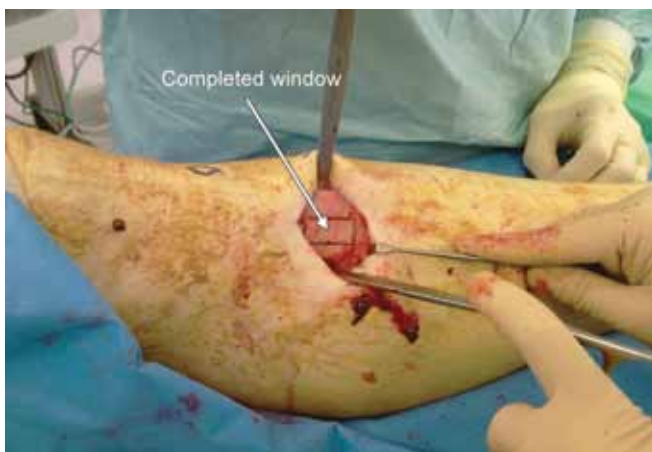

Fig. 3: Cortical window

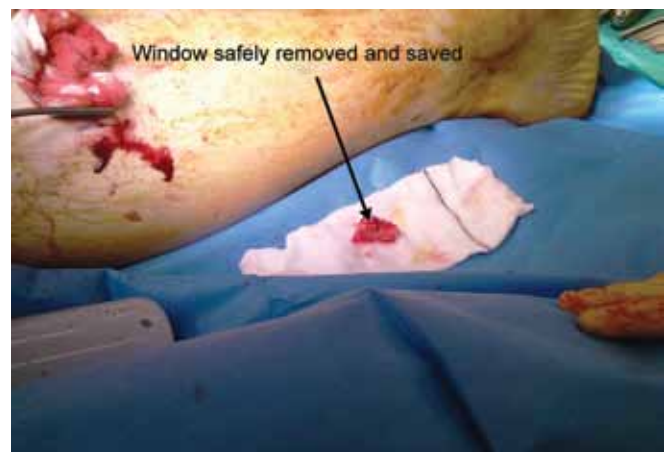


Fig. 4: Cortical window lifted out

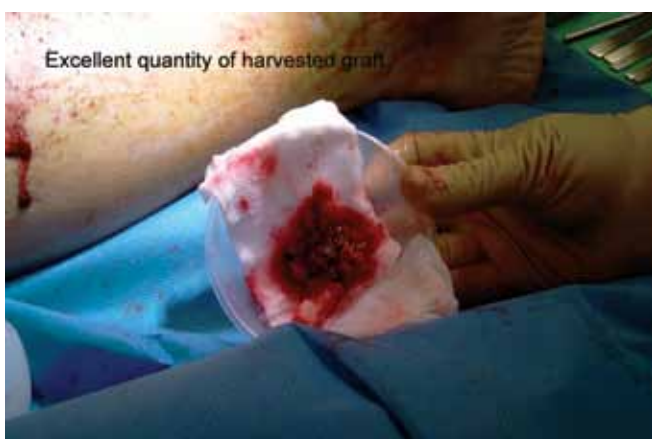

Fig. 5: Graft quantity

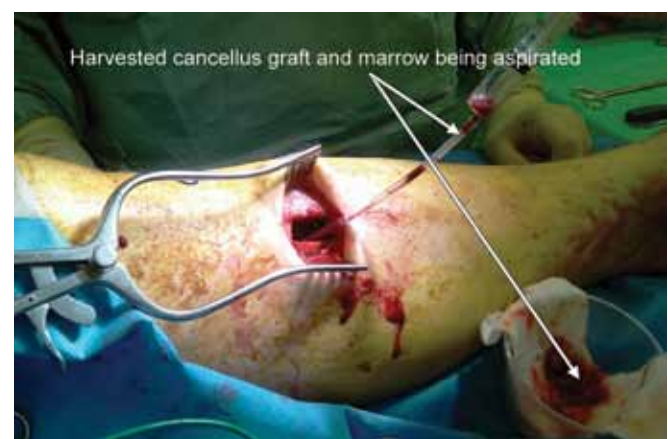

Fig. 6: Marrow harvesting

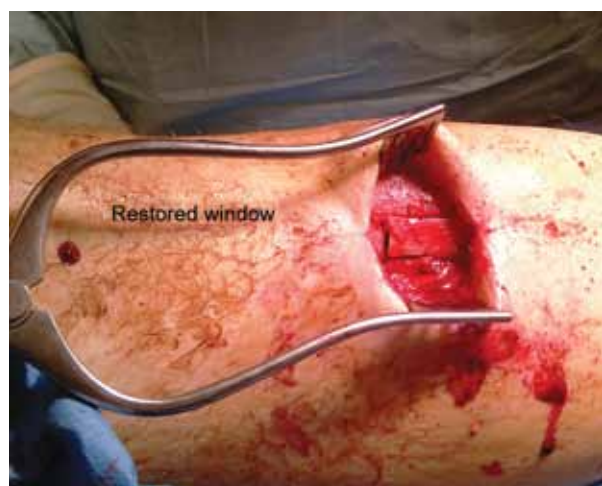

Fig. 7: Window repositioned

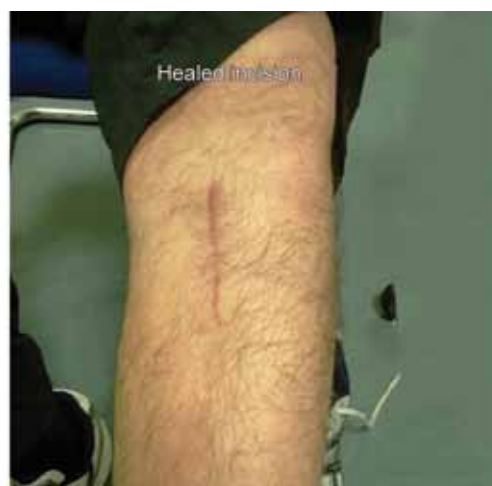

Fig. 8: Healed scar

Only three cases had postoperative complications. One case of superficial wound infection which resolved with antibiotics. Two patients had proximal tibial fracture through the graft area. Both patients had simple mechanical fall. The first patient had the injury at 6 weeks post-surgery and was treated nonoperatively. The second patient had the injury at 4 weeks post-surgery and was treated with open reduction and internal fixation (ORIF) (Figs 9 and 10).

DISCUSSION

Autogenous cancellous bone graft provides an osteoconductive, osteoinductive and osteogenic substrate for bone healing.¹ The proximal tibial metaphysis is a useful site for obtaining autogenous cancellous bone graft and is associated with a low morbidity.²⁻⁸ Up to 70 cm³ of cancellous graft can be obtained in young adults with good bone stock and is similar to the volume obtained from iliac crest.¹ The proximal tibia is a suitable site for bone graft harvest for foot and ankle surgery, because it is within the operative field and is under tourniquet control. There is no need for additional restrictions in weightbearing after this procedure.⁹

Anterior iliac crest has more hematopoietic marrow than any other graft harvest sites and hence is regarded as the gold standard site for bone graft harvest. However, many clinicians recognize considerable disadvantages to using iliac crest for graft harvest during foot and

ankle surgery. The most obvious problem is related to its anatomic location, requiring the preparation of a second surgical site.¹⁰

Traditionally, PTBGH is done by lateral approach. Various authors have described lateral PTBGH in maxillofacial surgery, foot and ankle surgery and in

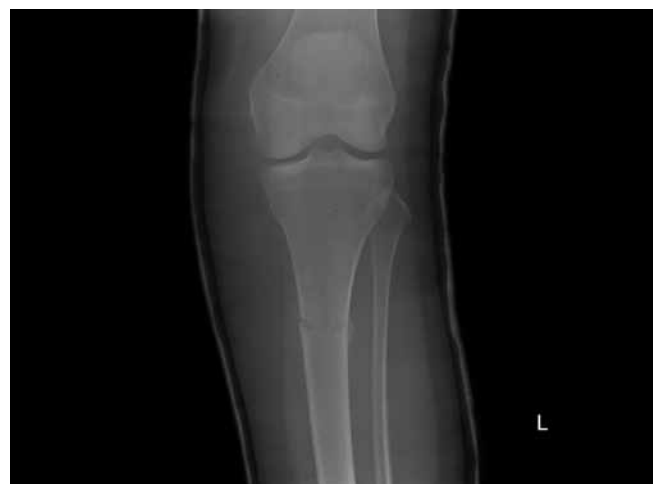

Fig. 9: Tibia fracture—4 weeks postoperative

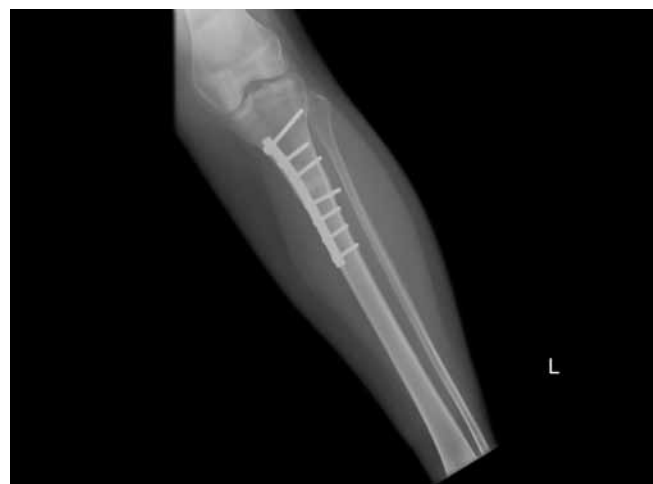

Fig. 10: Tibia fracture treated with ORIF

Table 1: Index procedures

Index procedures	Number of operations done
Revision first metatarsophalangeal joint fusion	22 (47.8%)
Subtalar joint fusion	9 (19.6%)
Tarsometatarsal joint fusion	8 (17.4%)
Talonavicular joint fusion	5 (10.9%)
Others	2 (4.3%)

trauma surgery with satisfactory results. However, lateral approach has difficult access and the lateral (interosseous) border of the tibia is vertical. Due to the attachment of iliotibial band and the risk breaching the joint, the cortical window should be made at or below the Gerdy's tubercle by elevating the superior fibers of tibialis anterior muscle. The lateral approach hence breach the anterior compartment and increase the risk of compartment syndrome.⁶ The branches of the recurrent tibial vessels and nerve coursing through the tibialis anterior muscles are at risk in the lateral approach. Medial approach has fewer serious structures in harm's way compared to lateral approach. However, lateral approach has the benefit of muscle coverage and hence it might be beneficial for patients with poor wound healing capacity (e.g. diabetics).¹¹ With either of these approaches, there is no difference with regards to the clinical results or the complications.^{6,12} Soohoo et al have quoted 93% union rate in foot and ankle procedures with PTBGH and confirms difficulties with lateral approach.⁸ Vienne et al have reported high patient satisfaction with lateral approach and suggested that it can be done under local or locoregional anesthesia.¹²

Alt et al have quoted an overall complication rate of 1.9% with PTBGH.² In their series, there were no major complications and immediate postoperative weight bearing did not have any deleterious effects. Geidman et al also confirmed similar findings. They reported three incidents of sensory changes at the incision site.⁵

CONCLUSION

Proximal medial tibial bone graft harvesting is a relatively safe and easy procedure to obtain adequate amount of autogenous cancellous bone graft for foot and ankle procedures. We believe our study is the largest series using medial approach.

Donor site morbidity is very low. Fusion rate was found to be excellent for foot and ankle procedures. Recovery from the index procedure was not affected and

hence is a cost-effective alternative to bone graft substitutes. As with other bone graft donor sites, the quality and quantity of grafts are adversely affected by age above 75 years. We strongly recommend this technique as a gold standard for foot and ankle fusion procedures.

REFERENCES

1. Myeroff C, Archdeacon M. Autogenous bone graft: donor sites and techniques. *J Bone Joint Surg Am* 2011 Dec;93(23):2227-2236.
2. Alt V, Nawab A, Seligson D. Bone grafting from the proximal tibia. *J Trauma* 1999 Sep;47(3):555-557.
3. Alt V, Meeder PJ, Seligson D, Schad A, Atienza C Jr. The proximal tibia metaphysis: a reliable donor sight for bone grafting? *Clin Orthop Relat Res* 2003 Sep;414:315-321.
4. Chen YC, Chen CH, Chen PL, Huang IY, Shen YS, Chen CM. Donor site morbidity after harvesting of proximal tibia bone. *Head Neck* 2006 Jun;28(6):496-500.
5. Geidman W, Early JS and Brodsky J. Clinical results of harvesting autogenous cancellous graft from the ipsilateral proximal tibia for use in foot and ankle surgery. *Foot Ankle Int* 2004 Jul;25(7):451-455.
6. Herford AS, King BJ, Audia F, Becktor J. Medial approach for tibial bone graft: anatomic study and clinical technique. *J Oral Maxillofac Surg* 2003 Mar;61(3):358-363.
7. O'Keeffe RM Jr, Riemer BL, Butterfield SL. Harvesting of autogenous cancellous bone graft from the proximal tibial metaphysis: a review of 230 cases. *J Orthop Trauma* 1991 Dec; 5(4):469-474.
8. Soohoo NE, Cracchiolo A. The results of utilizing proximal tibial bone graft in reconstructive procedures of the foot and ankle. *Foot Ankle Surg* 2008;14(2):62-66.
9. Whitehouse MR, Lankester BJ, Winson IG, Hepple S. Bone graft harvest from the proximal tibia in foot and ankle arthrodesis surgery. *Foot Ankle Int* 2006 Nov;27(11):913-916.
10. Winson IG, Higgs A. The use of proximal and distal tibial bone graft in foot and ankle procedures. *Foot Ankle Clin* 2010 Dec;15(4):553-558.
11. Benninger B, Ross A, Delmarter T. Approaches to proximal tibial bone harvest techniques. *J Oral Maxillofac Res* 2012 Apr-Jun;3(2):e2.
12. Vienne P, Maurer M, Jankauskas L. Autogenous bone grafting from proximal tibia in elective foot and ankle surgery: an analysis of 43 consecutive patients. *Fuss Sprungg* 2006;4(1): 54-58.