ORIGINAL ARTICLE

Salvage Technique for Failed ORIF in Diabetic Ankle Fractures: A Case Series

Ari R Berg[1], Nicholas F Cuppari[2], Mohamed Rupani[3], Sheldon Lin[4]

Abstract

Aim: This study describes a treatment algorithm for addressing failed ankle open reduction and internal fixation (ORIF) in diabetic patients using two successful patient cases.

Background: The complication rate following ankle fracture ORIF in diabetic patients is significantly higher compared to that in nondiabetic patients and salvage techniques are limited. Complications include soft tissue problems and increased infection rate, impaired bone healing and the possibility of a lost reduction, and Charcot arthropathy.

Case description: We analyze two cases of failed ORIF following traumatic ankle fracture in diabetic patients. Both patients underwent salvage procedures utilizing skinny wire external fixators with tibiotalocalcaneal stabilization *via* one or two Steinmann pins and were initiated on an 8-week course of IV antibiotics.

Conclusion: Use of external fixation with tibiotalocalcaneal Steinmann pin fixation and IV antibiotics is an effective treatment after failed ankle ORIF in diabetic patients.

Clinical significance: An algorithm to salvage failed ankle ORIF can help avoid the worst outcomes in diabetic patients.

Keywords: Ankle external fixator, Diabetic ankle, Diabetic ankle fracture, Failed ankle ORIF, Salvage ankle ORIF, Tibiotalocalcaneal fusion.

Journal of Foot and Ankle Surgery (Asia-Pacific) (2022): 10.5005/jp-journals-10040-1212

Background

Approximately 9.3% of adult fractures involve the ankle.[1] Of these fractures, 13% occur in patients who are diabetic, even before controlling for high-energy injury causes.[2] It is well documented that diabetic wound and bone healing is severely impaired, making lasting repair more challenging.[3] In fact, diabetics have a reported 3.4- fold increased risk of noninfectious complications following fracture treatment.[4] These include delayed union, nonunion, redislocation, and pseudoarthrosis.[5] Infection is also a concern with reports that up to 71% of diabetic patients get infected postfracture repair, with 43% being deep infections. The same study showed an infection rate of 19% for nondiabetics, of which 9% were deep infections.[6]

Treatment of ankle fractures in the diabetic population is notoriously fraught with complications. The complications that arise include soft tissue problems and associated increased infection rate, impaired bone healing and the possibility of a lost reduction, and Charcot arthropathy. Wukich et al. conducted a retrospective chart review of 1,000 patients and found wound complications to be present in 13.2% of diabetic patients following foot and ankle surgery, compared to just 2.8% of patients without diabetes.[7] Schmidt et al. performed a similar review of 979 patients and found a 26% complication rate following ORIF for ankle fractures in a diabetic cohort compared to 15% in a matched control group of nondiabetic patients. They found an incidence of 6.9% deep infections in diabetics compared to 1.3% in nondiabetics, and an unplanned procedure rate of 18.3% vs 9.1%.[8] A retrospective study of 45,444 patients performed by Pincus et al. concluded that there was a 7.42 Odds Ratio of having a postoperative amputation for diabetics following failed ORIF compared to the general population.[9] Finally, Loder et al. found a prolonged union time of 163% in patients with diabetes following ankle fracture.[3]

[1–4]Department of Orthopaedics, New Jersey Medical School, Newark, New Jersey, United States

Corresponding Author: Sheldon Lin, Department of Orthopaedics, New Jersey Medical School, Newark, New Jersey, United States, Phone: (973) 972-2184, e-mail: linss@njms.rutgers.edu

How to cite this article: Berg AR, Cuppari NF, Rupani M, *et al.* Salvage Technique for Failed ORIF in Diabetic Ankle Fractures: A Case Series . J Foot Ankle Surg (Asia-Pacific) 2022;9(S-1):S168–S172.

Source of support: Nil

Conflict of interest: None

Current options for ankle fracture repair following failed ORIF include nonoperative management in a CROW boot, repeat ORIF, staged reconstruction with antibiotic beads, external fixation, ankle fusion, or amputation. Each of these options, however, is not without complication. Given the complex nature of diabetic fracture healing, it is important to develop a protocol for salvage surgery following failed primary ankle ORIF. In this article, we present two cases of failed ankle ORIF and provide a simple algorithm for secondary repair of such fractures.

Case 1

A 55-year-old woman with a history of ischemic stroke with residual right hemiparesis, type I diabetes mellitus, epilepsy, and previous right hip fracture fixation presented with right ankle pain after a mechanical fall from standing. X-ray examination demonstrated a fracture-dislocation of the right ankle with lateral subluxation of the talus relative to the tibia (Figs 1A and B). Her

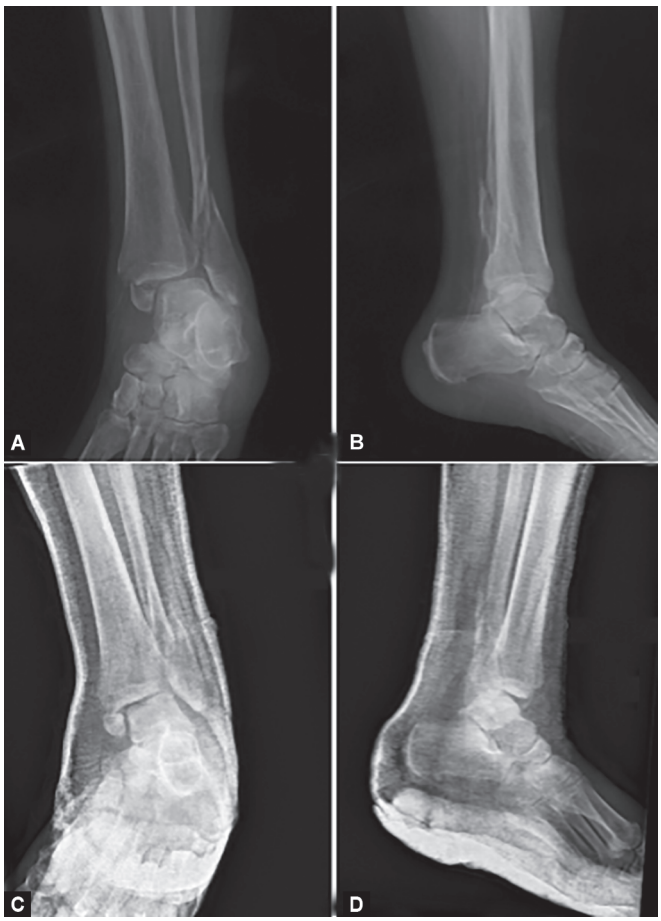

Figs 1 (A to D): (A and B) AP and lateral X-ray of the ankle demonstrating a fracture-dislocation with lateral subluxation of the talus in relation to the tibia. (C and D) Postreduction films at follow-up showing persistent posterior subluxation of the tibia

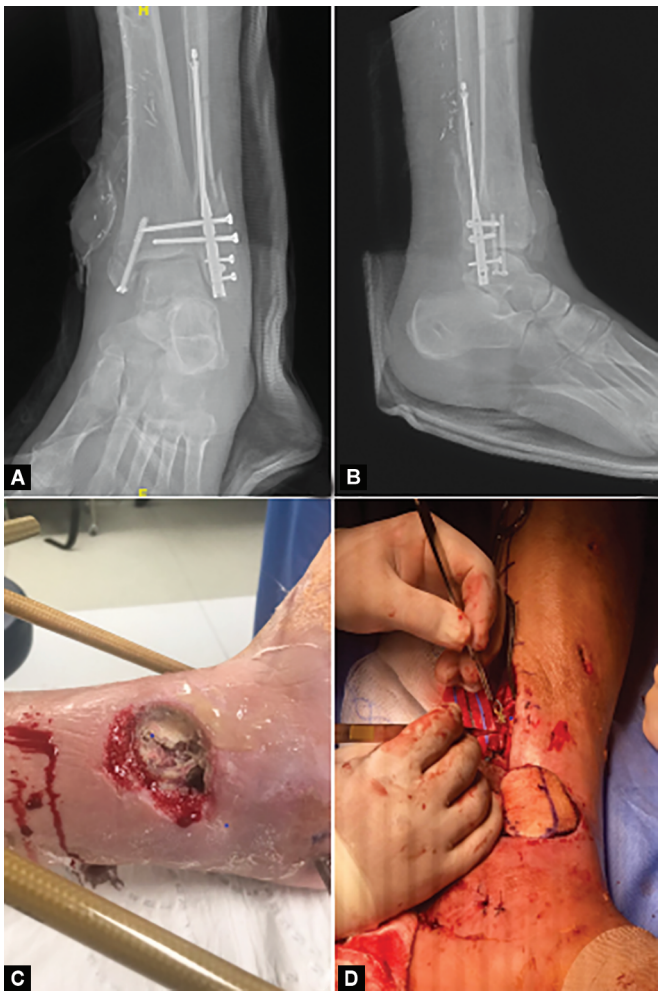

Figs 2 (A to D): (A and B) ORIF of trimalleolar ankle fracture with syndesmotic fixation. (C and D) Medial malleolus wound following irrigation and debridement, and subsequent radial forearm free flap

ankle was closed reduced and splinted; the patient was given follow up with the plan for definitive fixation once the ankle soft tissue swelling had subsided.

Upon initial follow-up visit three weeks following her presentation to the emergency room, X-rays revealed loss of reduction of her ankle fracture, as well as a wound over the medial malleolus (Figs 1C and D). IV antibiotics were initiated, the patient was taken to the operating room for irrigation and debridement of the ankle wound and an ankle-spanning external fixator was applied. The patient subsequently underwent a staged procedure with repeat I&D and ORIF of her fibula and syndesmosis, followed by percutaneous fixation of the medial malleolus, and radial forearm free flap to the ankle performed by plastic surgery (Fig. 2). The patient completed 6 weeks of IV antibiotics.

Two months following discharge from the hospital, the patient presented with pain, erythema and drainage from her left ankle wound. X-ray obtained at that time revealed nonunion of the trimalleolar ankle fracture with hardware failure and erosive changes throughout the ankle joint. At this point, the patient was diagnosed with a septic nonunion. She was taken back to the operating room for hardware removal and saucerization of the bone followed by skinny wire external fixation with a Taylor spatial frame and tibiotalocalcaneal stabilization with the use of a threaded Steinmann pin. Roughly 3 months later, definitive TTC fusion was performed with a lateral TTC fusion plate with Vivex bone graft and augment rhPDGF (Fig. 3). At the most recent follow-up 5 months following her TTC fusion, the patient was progressing well and she reported no issues. A custom AFO was fitted to maintain appropriate alignment of her foot and ankle and her weight bearing status was advanced.

Case 2

A 65-year-old man with a history of type II diabetes mellitus, seizure disorder, undifferentiated schizophrenia, subarachnoid bleeding, hyponatremia, long- standing persistent atrial fibrillation, and essential hypertension presented to the ER with complaints of left ankle pain, deformity and medial ankle wound with protruding bone after a fall. X-ray examination demonstrated a trimalleolar ankle fracture with lateral and posterior subluxation of the talus under the tibia. The patient was brought to the OR and underwent I&D, as well as ORIF with a fibular plate, two medial malleolar screws and a tetracortical syndesmotic screw (Fig. 4).

The patient presented to the ER 1 week postoperatively with ankle pain and medial wound dehiscence after not being compliant with his non-weight bearing status. X-rays showed the failure of hardware from both the tibia and fibula. The patient was brought back to the operating room for repeat I&D, application of an ankle-spanning external fixator and tibiotalocalcaneal fusion

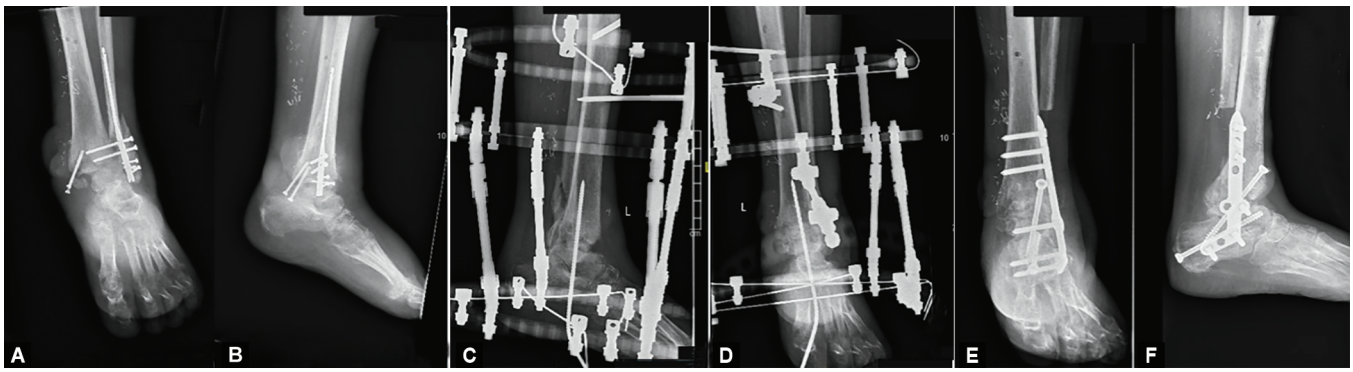

Figs 3 (A to F): (A and B) Hardware failure following ORIF trimalleolar ankle fracture. (C and D) Application of skinny wire Taylor spatial frame and a Steinmann pin through the TTC joint. (E and F) Following TTC fusion with a lateral TTC fusion plate

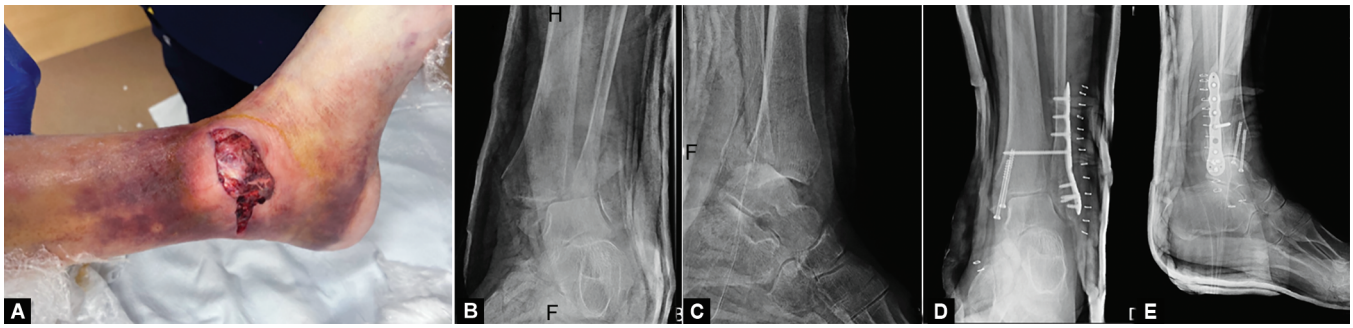

Figs 4 (A to E): (A) Medial ankle wound with exposed bone. (B and C) AP and lateral view of the left ankle show a trimalleolar ankle fracture with lateral and posterior subluxation of the talus. (D and E) Following ORIF

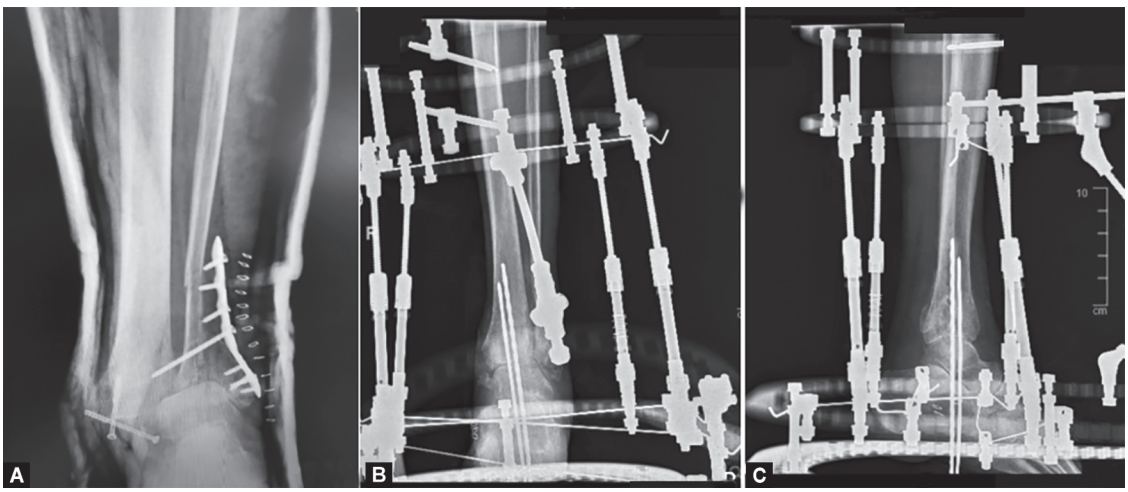

Figs 5 (A to C): (A) Hardware failure of both the tibia and fibula fixation. (B and C) Following ankle-spanning external fixation and TTC fusion with two Steinmann pins

with two Steinmann pins (Fig. 5). He was subsequently discharged from the hospital and continued on IV antibiotics for 8 weeks. At the most recent follow up, roughly 1 year following surgery, the patient was doing well with no pain to his left ankle. His wounds were healed and he was fitted for a custom AFO.

Discussion

In this paper, we present a case series of two diabetic patients with failed ORIF following ankle fracture treated with a unique salvage technique. We propose the following algorithm: first, removal of present hardware, debridement of wound and cultures to determine the appropriate antibiotic treatment. Next, skinny wire external fixation should be placed with a Steinmann pin inserted through the tibiotalocalcaneal bones to immobilize the area and allow for proper healing. Additionally, while in the external fixator, the patient should begin an 8-week course of IV antibiotics. At the end of this period, if bone healing has not progressed, tibiotalocalcaneal arthrodesis *via* lateral plate or retrograde TTC nailing should be considered.

This salvage technique offers a number of advantages. For one, the construct consists entirely of skinny wire external fixation and one or two Steinmann pins for tibiotalocalcaneal fixation. There is therefore no retained metal from the initial ORIF. This provides the opportunity for wound and bone healing and mitigates the risk of further deep infection or osteomyelitis. Finally, it is a relatively easy procedure with short OR time as well as minimal blood loss and soft tissue disruption.

Management of unstable ankle fractures in diabetics is a difficult problem and a number of different techniques have been posited. Transcalcaneal-talar-tibial fixation using large Steinmann pins and circular external fixation in conjunction with primary ORIF have been described in the literature.[10,11] Limb salvage following failed diabetic ankle ORIF poses an even more challenging scenario. Vaudreuil et al. performed a retrospective review of diabetic patients who sustained a bimalleolar ankle fracture and failed initial operative management. They found that all patients who went on to amputation presented initially with infection and were treated with revision ORIF. In contrast, all patients who achieved successful limb salvage ended up with a clinically fused ankle joint.[12] Guerrero-Maestre et al. described a case report of a 52-year-old woman with uncontrolled diabetes who was initially treated with ORIF for a bimalleolar fracture that eventually progressed to Charcot arthropathy. They presented a limb-salvage technique similar to the one described in this study, in which they combined a hindfoot fusion nail with adjuvant external fixation. Postoperative visits demonstrated wound healing without complications and painless weight bearing.[13]

While hindfoot fusion is an attractive salvage technique, it is not without complications of its own, most notably nonunion which has been reported to be as high as 40% in certain populations.[14,15] Arthrodesis is frequently supplemented with autogenous bone graft, however this is associated with donor site morbidity such as blood loss, chronic pain, seroma, infection, hernia, and nerve injury.[16-18] Suitable alternatives to autograft include bone and tissue growth factors such as recombinant human platelet-derived growth factor (rhPDGF). DiGiovanni et al. performed a prospective, randomized controlled trial of 434 patients requiring hindfoot or ankle arthrodesis and determined that treatment with rhPDGF-BB in a beta-tricalcium phosphate (B-TCP) scaffold resulted in comparable fusion rates, less pain and fewer side effects compared to treatment with autograft.[19] Further studies, including one propensity score subclassification analysis of three randomized controlled trials, demonstrated that rhPDGF-BB/B-TCP-collagen was as effective as autograft for hindfoot and ankle fusions, with less pain and morbidity when compared to autograft.[20-24]

This case series presents a convincing case for salvage technique following failed diabetic ankle ORIF due to infection and outlines an algorithm of treatment. We have had success with this technique at our institution. Nevertheless, there are limitations to this study. Firstly, this is a case report, which carries with it inherent biases. The evidence is purely anecdotal at this point and requires further retrospective reviews and prospective trials to make conclusive statements regarding efficacy. Furthermore, these are relatively recent cases, without long-term follow up.

In conclusion, ankle fractures in the diabetic population are difficult to manage and salvage techniques following failed ORIF are limited. Use of skinny wire external fixation with tibiotalocalcaneal Steinmann pin fixation and IV antibiotics has been shown to be an effective treatment after failed ankle ORIF in two diabetic patients. Future steps include retrospective reviews as well as a randomized controlled trial to assess the efficacy of this salvage technique compared to revision ORIF. Analysis of the concomitant use of bone and tissue growth factors such as rhPDGF should also be studied. Utilization of the described technique may help in reducing the incidence of subsequent infection and the need for more drastic measures such as amputation.

Clinical Significance

An algorithmic approach to failed ankle ORIF in the diabetic population can aid in reducing the incidence of osteomyelitis and subsequent amputation.

References

1. Court-Brown CM, Caesar B. Epidemiology of adult fractures: a Review. Injury 2006;37(8):691–697. DOI: 10.1016/j.injury.2006.04.130
2. Gougoulias N, Oshba H, Dimitroulias A, et al. Ankle fractures in diabetic patients. EFORT Open Rev 2020;5(8):457–463. DOI: 10.1302/2058-5241.5.200025
3. Loder RT. The influence of diabetes mellitus on the healing of closed fractures. Clin Orthop Relat Res 1988;(232):210–216. ISSN: 0009-921X , 0009-921X; PMID: 3289812.
4. Folk JW, Starr AJ, Early JS. Early wound complications of operative treatment of calcaneus fractures: analysis of 190 fractures. J Orthop Trauma 1999;13(5):369-372. DOI: 10.1097/00005131-199906000-00008
5. Stuart MJ, Morrey BF. Arthrodesis of the diabetic neuropathic ankle joint. Clin Orthop Relat Res 1990;(253):209–211. ISSN: 0009-921X, 0009-921X; PMID: 2317976.
6. Kline AJ, Gruen GS, Pape HC, et al. Early complications following the operative treatment of pilon fractures with and without diabetes. Foot Ankle Int 2009;30(11):1042–1047. DOI: 10.3113/FAI.2009.1042
7. Wukich DK, Joseph A, Ryan M, et al. Outcomes of ankle fractures in patients with uncomplicated versus complicated diabetes. Foot Ankle Int 2011;32(2):120–130. DOI: 10.3113/FAI.2011.0120
8. Schmidt T, Simske NM, Audet MA, et al. Effects of diabetes mellitus on functional outcomes and complications after torsional ankle fracture. J Am Acad Orthop Surg 2020;28(16):661–670. DOI: 10.5435/JAAOS-D-19-00545
9. Pincus D, Veljkovic A, Zochowski T, et al. Rate of and risk factors for intermediate-term reoperation after ankle fracture fixation: A population-based cohort study. J Orthop Trauma 2017;31(10):e315–e320. DOI: 10.1097/BOT.0000000000000920
10. Facaros Z, Ramanujam CL, Stapleton JJ. Combined circular external fixation and open reduction internal fixation with pro-syndesmotic screws for repair of a diabetic ankle fracture. Diabet Foot Ankle 2010;1. DOI: 10.3402/dfa.v1i0.5554
11. Jani MM, Ricci WM, Borrelli J Jr, et al. A protocol for treatment of unstable ankle fractures using transarticular fixation in patients with diabetes mellitus and loss of protective sensibility. Foot Ankle Int 2003;24(11):838–844. DOI: 10.1177/107110070302401106
12. Vaudreuil NJ, Fourman MS, Wukich DK. Limb salvage after failed initial operative management of bimalleolar ankle fractures in diabetic neuropathy. Foot Ankle Int 2017;38(3):248–254. DOI: 10.1177/1071100716676063
13. Guerrero-Maestre RG, Beaton-Comulada D, Colon-Miranda R. Hindfoot fusion nail with adjuvant hybrid external fixation used as limb-salvage procedure after failed open reduction internal fixation of ankle fracture in a charcot joint: a case report. P R Health Sci J 2018;37(4):235–238. PMID: 30548061.
14. Coughlin MJ, Grimes JS, Traughber PD, et al. Comparison of radiographs and CT scans in the prospective evaluation of the fusion of hindfoot arthrodesis. Foot Ankle Int 2006;27(10):780–787. DOI: 10.1177/107110070602701004
15. Frey C, Halikus NM, Vu-Rose T, et al. A review of ankle arthrodesis: predisposing factors to nonunion. Foot Ankle Int 1994;15(11):581–584. DOI: 10.1177/107110079401501102

16. Chou LB, Mann RA, Coughlin MJ, et al. Stress fracture as a complication of autogenous bone graft harvest from the distal tibia. Foot Ankle Int 2007;28(2):199–201. DOI: 10.3113/fai.2007.0199
17. Boone DW. Complications of iliac crest graft and bone grafting alternatives in foot and ankle surgery. Foot Ankle Clin 2003;8(1):1–14. DOI: 10.1016/s1083-7515(02)00128-6
18. Kirmeier R, Payer M, Lorenzoni M, et al. Harvesting of cancellous bone from the proximal tibia under local anesthesia: donor site morbidity and patient experience. J Oral Maxillofac Surg 2007;65(11):2235–2241. DOI: 10.1016/j.joms.2006.11.038
19. DiGiovanni CW, Lin SS, Baumhauer JF, et al. Recominant human platelet-derived growth factor-BB and beta-tricalcium phosphate (rhPDGF-BB/B-TCP): an alternative to autogenous bone graft. J Bone Joint Surg Am 2013;95(13):1184–1192. DOI: 10.2106/JBJS.K.01422
20. Digiovanni CW, Baumhauer J, Lin SS, et al. Prospective, randomized, multi-center feasibility trial of rhPDGF-BB versus autologous bone graft in a foot and ankle fusion model. Foot Ankle Int 2011;32(3):344–354. DOI: 10.3113/FAI.2011.0344
21. Daniels T, DiGiovanni C, Lau JT, et al. Prospective clinical pilot trial in a single cohort group of rhPDGF in foot arthrodeses. Foot Ankle Int 2010;31(6):473–479. DOI: 10.3113/FAI.2010.0473
22. Daniels TR, Anderson J, Swords MP, et al. Recombinant human platelet-derived growth factor BB in combination with a beta-tricalcium phosphate (rhPDGF-BB/beta-TCP)—collagen matrix as an alternative to autograft. Foot Ankle Int 2019;40(9):1068–1078. DOI: 10.1177/1071100719851468
23. Daniels TR, Younger AS, Penner MJ, et al. Prospective randomized controlled trial of hindfoot and ankle fusions treated with rhPDGF-BB in combination with a beta-TCP-collagen matrix. Foot Ankle Int 2015;36(7):739–748. DOI: 10.1177/1071100715576370
24. Berlet GC, Baumhauer JF, Glazebrook M, et al. The impact of patient age on foot and ankle arthrodesis supplemented with autograft or an autograft alternative (rhPDGF-BB/beta-TCP). JB JS Open Access 2020;5(4):e20.00056. DOI: 10.2106/JBJS.OA.20.00056