

# Short Scarf Osteotomy for Hallux Valgus: Short-term and Medium-term Results

<sup>1</sup>Rakesh Dalal, <sup>2</sup>Rajesh Rachha, <sup>3</sup>David Leonard, <sup>4</sup>Ajay Chourasia, <sup>5</sup>Saqib Javed

## ABSTRACT

**Aim:** The scarf osteotomy, as popularized by Barouk, is a versatile osteotomy for the correction of moderate and severe hallux valgus deformity. However, this technique requires extensive exposure, fixation, and increased operative time, and is technically demanding. We describe and present our results of a short scarf osteotomy (SSO), which retains all the cuts of a standard scarf but requires a reduced exposure, less metalwork, less operating time, and is more economical.

**Materials and methods:** All patients who underwent SSO between January 2010 and December 2012 with minimum follow-up of 12 months were eligible for the study. Preoperative, intraoperative, and postoperative radiographs were available for radiological assessment.

**Results:** In this study, 84 patients and 94 feet were included; 90% of patients were satisfied overall, with 83% of patients recommending this surgery to a friend. The hallux valgus angle improved from a preoperative mean of 30.89° (17.4–46.8) to 12° (4–30) postoperatively ( $p = 0.0001$ ). The intermetatarsal angle improved from a preoperative mean of 15.05° (10.3–21.1) to 7.14° (4–15.1) postoperatively ( $p = 0.0001$ ). The average sesamoid coverage improved from grade 2.18 (1–3) preoperatively to 0.57 (0–2) postoperatively ( $p = 0.0001$ ). The average American Orthopedic Foot and Ankle Score improved from 51.26 (32–88) preoperatively to 91.1 (72–100) postoperatively ( $p = 0.0001$ ).

**Conclusion:** We believe that this osteotomy is a novel procedure producing good to excellent results in most cases of hallux valgus. Biologically, the decreased exposure should improve healing and reduce the risk of avascular necrosis. We strongly recommend this osteotomy for most cases of hallux valgus surgery.

**Keywords:** Hallux, Osteotomy, Scarf, Shor, Valgus.

**How to cite this article:** Dalal R, Rachha R, Leonard D, Chourasia A, Javed S. Short Scarf Osteotomy for Hallux Valgus: Short-term and Medium-term Results. *J Foot Ankle Surg (Asia-Pacific)* 2017;4(1):14-18.

**Source of support:** Nil

**Conflict of interest:** None

<sup>1</sup>Consultant, <sup>2</sup>Clinical Fellow, <sup>3,5</sup>Specialty Trainee, <sup>4</sup>Foundation Doctor

<sup>1,5</sup>Department of Trauma and Orthopaedics, Stepping Hill Hospital, Stockport, Greater Manchester, UK

<sup>2-4</sup>Department of Orthopaedics, Stepping Hill Hospital, Stockport Greater Manchester, UK

**Corresponding Author:** Rakesh Dalal, Consultant, Department of Trauma and Orthopaedics, Stepping Hill Hospital, Stockport Greater Manchester, UK, Phone: +00441614831010, e-mail: rakesh.dalal@stockport.nhs.uk

## INTRODUCTION

The short scarf osteotomy (SSO) for bunions has been described by some authors in the 1980s, reporting technical difficulties and metalwork problems.<sup>1-4</sup> Various modifications of the scarf osteotomy have been described with reasonable outcomes.<sup>5-8</sup> The standard long scarf osteotomy as popularized by Barouk<sup>9</sup> is a reliable and versatile technique for the correction of moderate and severe hallux valgus. However, it is technically demanding, involves a longer exposure, extensive soft tissue dissection with attendant risks of increased blood supply stripping and fracture. We describe our experience with the SSO, which combines virtually all the advantages of a standard scarf, but with the added benefits of reduced surgical exposure, less metalwork, decreased operative time, and with satisfactory clinical and radiological outcomes.

## MATERIALS AND METHODS

All patients who underwent SSO between January 2010 and December 2012 were eligible for the study (98 patients). Those patients who had less than 1 year follow-up or had any additional first ray procedures performed were excluded from the statistical evaluation, leaving 84 patients and 94 feet for evaluation. Our exclusion criteria for this study were infection, peripheral vascular disease, inflammatory pathology, hallux rigidus, and any previous surgery to the hallux.

Minimum follow-up was 12 months (12–28). Preoperative, intraoperative, and postoperative radiographs were available for radiological assessment. Intraoperative parameters used were length of surgical incision, length of bone exposure, fixation used, and operating time. All patients had weight-bearing radiographs preoperatively and postoperatively. Radiological assessment included measuring of sesamoid coverage, hallux valgus angle (HVA) and intermetatarsal angle (IMA) preoperatively and postoperatively. All the radiological parameters were measured by an independent single investigator to avoid interobserver errors. Sesamoid coverage was graded using tibial sesamoid position in relation to Reynold stations (Fig. 1).<sup>10</sup> Radiological grading of the deformity was assessed as per Mann's classification (Table 1).<sup>11</sup>

The (AOFAS) scoring was done preoperatively and at final follow-up.<sup>12</sup> Overall patient satisfaction was

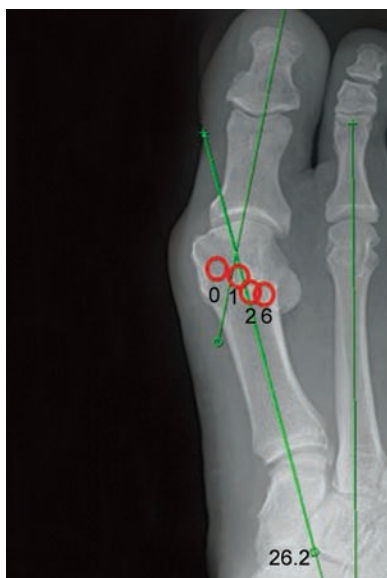

Fig. 1: Tibial sesamoid position grading: Grades 0 to 3

also assessed by using a global satisfaction questionnaire asking about overall satisfaction of the procedure, symptom relief, and if they would recommend the surgery to a friend. Nonparametric Mann–Whitney U test was used to check the statistical significance of our results.

### Surgical Technique

The procedure is performed under regional or general anesthesia using an ankle tourniquet. The patient is supine with a sand bag under the ipsilateral buttock. A single dose of intravenous antibiotic is administered. Firstly, a lateral soft tissue release is performed through a first web space dorsal incision releasing the adductor hallucis and the suspensory ligament in addition to a capsulotomy of the metatarsophalangeal joint (MTPJ) capsule. Through a medial incision not more than 3 cm long, the capsule is

Table 1: Mann's classification of deformity

	HVA (degrees)	IMA (degrees)
Mild	0–19	0–13
Moderate	20–40	14–20
Severe	>40	>20

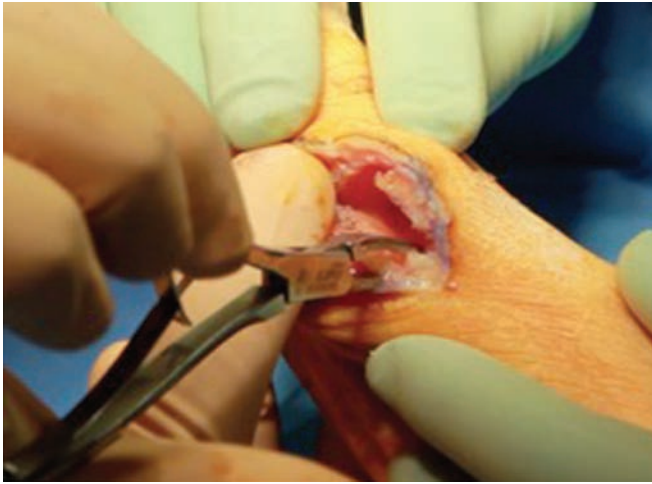
opened. The joint and the distal metatarsal are exposed. A cheilectomy of the MTPJ is performed. A “Z”-shaped step cut is marked (Fig. 2). A transverse hole with a K-wire is made at the distal end of the horizontal limb to avoid a stress riser (Fig. 3) and this is then followed by the osteotomy. The horizontal limb or the longitudinal cut of the SSO is made first along the length of the diaphysis. This longitudinal cut averages no more than 2.5 cm. The geometry of this cut is made in such a way as to achieve either lowering of the metatarsal head by starting more dorsally distally and extending it more plantar as it passes laterally or by starting the cut more centrally if we do not want lowering of the metatarsal head. The proximal plantar and the distal dorsal cuts are made as for a standard scarf to complete the “Z” osteotomy. The proximal cut is made with a double parallel cut technique so that adjustments in the distal metatarsal articular angle (DMAA) can be made (Fig. 4). Once the osteotomy is complete, required displacements can be achieved by translating the head and the plantar osteotomy fragment laterally. After the required displacement is achieved, the displaced osteotomy is temporarily fixed with a K-wire (Fig. 5). With a swab in the first web space, the position is checked for a simulated weight-bearing position and image intensifier is used to confirm satisfactory correction and sesamoid coverage (Fig. 6). Once we are satisfied with the correction achieved, the osteotomy is secured by inserting a single differential pitch 3.00 mm cannulated headless compression screw (Fig. 7). The excess bone sliver on the medial side of the metatarsal is excised and this can be placed

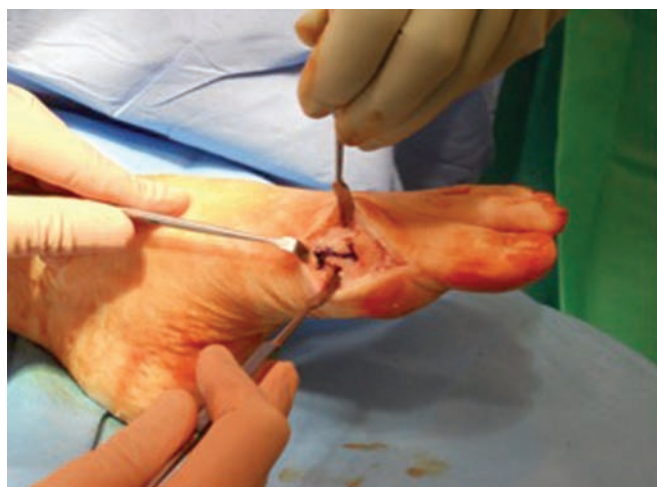

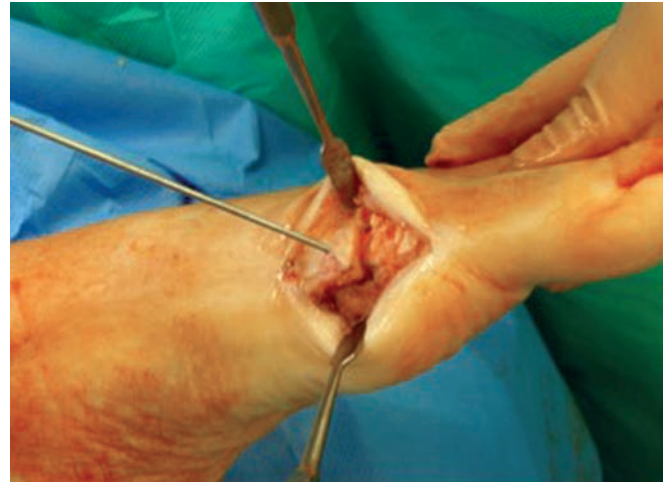
Fig. 2: “Z”-shaped step cut is marked

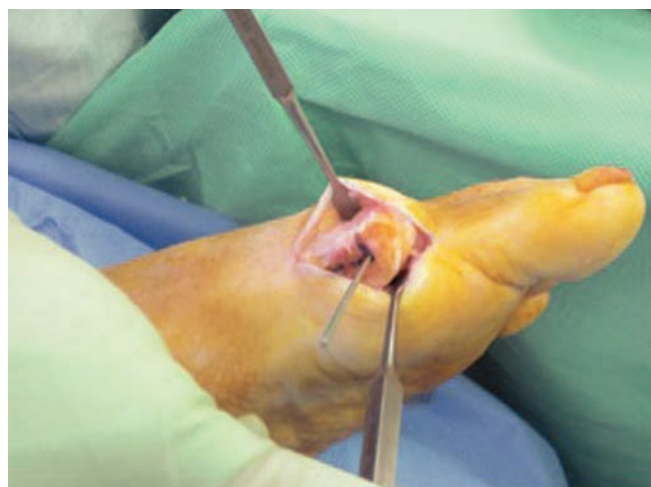

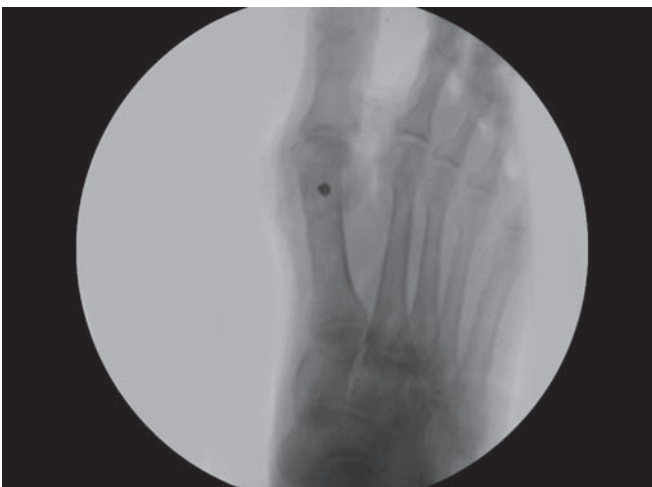Fig. 3: A transverse hole with a K-wire is made at the apex of the distal cut to avoid a stress riser before the osteotomy



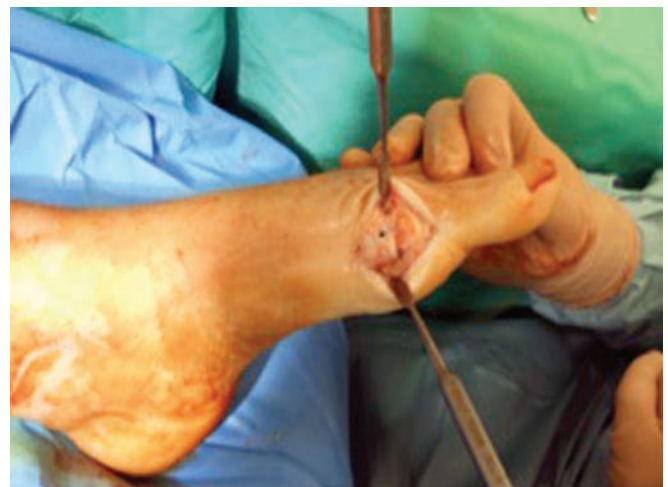**Fig. 4:** Sliver of bone excised following double parallel cut technique of the proximal plantar limb to allow adjustments in the DMAA



**Fig. 5:** After the required displacement is achieved, the displaced osteotomy is temporarily fixed with a K-wire



**Fig. 6:** Intraoperative simulated weight-bearing X-ray to confirm satisfactory correction and tibial sesamoid position



**Fig. 7:** Osteotomy is secured by a single differential pitch 3.00 mm cannulated headless compression screw

in the gap created in the proximal plantar osteotomy. A medial capsulorrhaphy is then performed with a No. 2 vicryl suture, ensuring relocation of the sesamoids in their respective sulcus. The wounds are then closed in layers with absorbable sutures and a compression dressing applied. A postoperative shoe with a posterior heel raise is used for partial weight bearing for 3 weeks. The dressings are changed at 3 weeks and full weight bearing permitted at this stage. At 3 weeks, weight-bearing dorso-plantar and lateral radiographs are performed and a referral to physiotherapy made. Further follow-up takes place at 3 and 6 months. For the purpose of this study, a minimum further follow-up at 12 months was also made (12–28 months) with radiographs and AOFAS scoring at final follow-up.

**RESULTS**

There were 4 males and 80 females. The age range was 24 to 81 with an average age of 50.9. All the preoperative

**Table 2:** Mean improvement in the radiological and clinical scoring

	HVA (degrees)	IMA (degrees)	Sesamoid coverage	AOFAS score
Preoperative mean	30.89	15.05	2.18	51.26
At follow-up	12	7.14	0.57	91.1
Mean improvement	18.89	7.91	1.61	39.84
p-value	0.0001	0.0001	0.0001	0.0001

radiological parameters significantly improved postoperatively (Table 2). Overall, 90% of patients were satisfied, with 83% of patients recommending this surgery to a friend. The HVA improved from a preoperative mean of 30.89° (17.4–46.8) to 12° (4–30) postoperatively (p = 0.0001). The IMA improved from a mean of 15.05° (10.3–21.1) to 7.14° (4–15.1) postoperatively (p = 0.0001). The average sesamoid coverage improved from grade 2.18 (1–3) preoperatively to 0.57 (0–2) postoperatively (p = 0.0001).<sup>13,14</sup> The average AOFAS score improved from 51.26 (32–88) preoperatively to 91.1 (72–100) postoperatively (p = 0.0001).

There were four radiological over corrections, three of which did not require any further surgery. Two patients had persistent pain due to arthritic changes and a further two patients had superficial wound infections treated with oral antibiotics. We did not have any fractures and did not notice the troughing phenomenon. There was one case of recurrence at 18 months postoperatively and this was successfully treated with a standard scarf osteotomy.

## DISCUSSION

The first critical evaluation of the SSO was published in 1987 using a single 2.7 mm cortical screw or a 3.5 mm fully threaded cancellous screw and they concluded it to be technically demanding.<sup>2</sup> Schwartz and Groves<sup>3</sup> have published their results of the SSO using 0.062 mm K-wires. Glickman and Zahari<sup>4</sup> used 0.045 mm K-wires to fix their SSO. They had complications of wires backing out as well as elevation and shortening of the metatarsal. We used 3.0 mm fully threaded differential pitch headless compression cannulated screws in all cases. This gives excellent stability with no problems of the screw backing out or any other metalwork-related problems.

Distal metatarsal osteotomies like chevron carries a risk of avascular necrosis (AVN) and are limited to mild deformities.<sup>13-15</sup> Though the sagittal split osteotomy (SSO) is a distal osteotomy, the proximal limb of the cut is well proximal to the plantar artery and, therefore, AVN is not a risk. We did not have any cases of AVN of the metatarsal head. Contrary to other distal metatarsal osteotomies, the SSO is more stable and versatile in achieving deformity correction and a more predictable repositioning of the metatarsal head. Additionally, a lateral soft tissue release, repositioning of the metatarsal head and a medial capsuloraphy are all important for a successful outcome from hallux valgus surgery.<sup>9</sup>

One of the risks of a standard long scarf osteotomy is fracture of the metatarsal intraoperatively or stress fractures in the postoperative period.<sup>16</sup> The SSO gives a stable fixation with good correction without risking fracture of the metatarsal due to its short lever arm. The occurrence of troughing with scarf osteotomy has been well documented in the literature.<sup>16-18</sup> Barouk<sup>9</sup> indicates an increased risk of troughing with a SSO. However, in our series we did not notice any troughing and one should exercise caution and be aware of this potential complication in order to avoid it, especially in osteoporotic bone.

Revision of a failed standard scarf is very difficult when compared to a failed SSO. In cases of a failed SSO or recurrence, it can be revised using the standard long scarf osteotomy. In our series we revised only one case for recurrence with a standard scarf, without any technical difficulties.<sup>19-22</sup>

Some of the limitations of our study are that there is no randomization or control group. A longer follow-up may be required to assess recurrence and/or progression of arthritis in the first MTPJ as a result of this osteotomy and its biomechanical effect on the first MTPJ. Though our AOFAS scores have improved satisfactorily following this surgery, we excluded additional first ray procedures in our statistical evaluation and it may be of interest to look in to the effect of additional forefoot procedures with relation to hallux surgery.

## CONCLUSION

Our short- and medium-term results of the SSO are satisfactory and can be recommended for most cases of hallux valgus surgery. It enables correction of moderate and severe deformities, including the DMAA without the extensive soft tissue exposure. The limitations are in revision situations, in cases requiring excessive DMAA correction and the very rare case where extensive lengthening would be required. Biologically, the decreased exposure should improve healing and reduce the risk of AVN. We believe that the use of intraoperative simulated weight-bearing radiographs is essential for assessing correction and achieving successful outcomes.

## REFERENCES

1. Zygmunt KH, Gudas CJ, Laros GS. Z-bunionectomy with internal screw fixation. *J Am Podiatr Med Assoc* 1989 Jul;79(7):322-329.
2. Pollack RA, Bellacosa RA, Higgins KR, Sharp BE, McCloskey TF. Critical evaluation of the short "Z" bunionectomy. *J Foot Surg* 1989 Mar-Apr;28(2):158-161.
3. Schwartz N, Groves ER. Long-term follow-up of internal threaded Kirschner-wire fixation of the scarf bunionectomy. *J Foot Surg* 1987 Jul-Aug;26(4):313-316.
4. Glickman S, Zahari DT. Short "Z" bunionectomy. *J Foot Surg* 1986 Jul-Aug;25(4):304-306.
5. Kramer J, Barry LD, Helfman DN, Mehnert JA, Pokrifcak VM. The modified scarf bunionectomy. *J Foot Surg* 1992 Jul-Aug;31(4):360-367.
6. Weil LS, Borelli AN. Modified scarf bunionectomy: our experience in more than 1000 cases. *J Foot Surg* 1991;30(609):e22.
7. Weil LS. Scarf osteotomy for correction of hallux valgus. Historical perspective, surgical technique, and results. *Foot Ankle Clin* 2000 Sep;5(3):559-580.
8. Duke HF. Rotational Scarf (Z) osteotomy bunionectomy for correction of high intermetatarsal angles. *J Am Podiatr Med Assoc* 1992 Jul;82(7):352-360.
9. Barouk LS. Scarf osteotomy for hallux valgus correction. Local anatomy, surgical technique, and combination with other forefoot procedures. *Foot Ankle Clin* 2000 Sep;5(3):525-528.
10. Smith RW, Reynolds JC, Stewart MJ. Hallux valgus assessment: report of research committee of American Orthopaedic Foot and Ankle Society. *Foot Ankle* 1984 Sep-Oct;5(2):92-103.

11. Mann, RA.; Coughlin, MJ. Adult hallux valgus. In: Coughlin, MJ.; Mann, RA., editors. *Surgery of the foot and ankle*. 7th ed. St. Louis: Mosby; 1999. p. 150-269.
12. Kitaoka HB, Alexander IJ, Adelaar RS, Nunley JA, Myerson MS, Sanders M. Clinical rating systems for the ankle-hind foot, midfoot, hallux, and lesser toes. *Foot Ankle Int* 1994 Jul;15(7):349-353.
13. Wilson JD, Baines J, Siddique MS, Fleck R. The effect of sesamoid position on outcome following scarf osteotomy for hallux abducto valgus. *Foot Ankle Surg* 2009;15(2):65-68.
14. David-West KS, Moir JS. Radiological assessment of tibial sesamoid position after Scarf osteotomy for Hallux valgus correction. *Foot Ankle Surg* 2002 Sep;8(3):209-212.
15. Wilkinson SV, Jones RO, Sisk LE, Sunshin KF, Van Manen JW. Austin bunionectomy: postoperative MRI evaluation for avascular necrosis. *J Foot Surg* 1992 Sep-Oct;31(5):469-477.
16. Meisenhelder DA, Harkless LB, Patterson JW. Avascular necrosis after first metatarsal head osteotomies. *J Foot Surg* 1984 Nov-Dec;23(6):429-435.
17. Resch S, Stenström A, Gustafson T. Circulatory disturbance of the first metatarsal head after chevron osteotomy as shown by bone scintigraphy. *Foot Ankle* 1992 Mar-Apr;13(3):137-142.
18. Smith AM, Alwan T, Davies MS. Perioperative complications of the Scarf osteotomy. *Foot Ankle Int* 2003 Mar;24(3):222-227.
19. Coetzee JC. Scarf osteotomy for hallux valgus repair: the dark side. *Foot Ankle Int* 2003 Jan;24(1):29-33.
20. Coetzee JC, Rippstein P. Surgical strategies: scarf osteotomy for hallux valgus. *Foot Ankle Int* 2007 Apr;28(4):529-535.
21. Murawski CD, Egan CJ, Kennedy JG. A rotational scarf osteotomy decreases troughing when treating hallux valgus. *Clin Orthop Relat Res* 2011 Mar;469(3):847-853.
22. Rothwell M, Pickard J. The chevron osteotomy and avascular necrosis. *Foot (Edinb)* 2013 Mar;23(1):34-38.