

# Revision Ankle Syndesmosis Fixation: Functional Outcome after TightRope<sup>®</sup> Fixation

<sup>1</sup>Senthil Rajagopalan, <sup>2</sup>Pradeep Moonot, <sup>3</sup>Anurag Sangar, <sup>4</sup>Heath Taylor

## ABSTRACT

**Introduction:** Syndesmotic injuries present a challenge to orthopedic surgeons. Malreduction of the syndesmosis has been reported to cause instability and secondary osteoarthritis and is correlated with poor subjective and objective outcomes. There are very few studies that report the outcome after revision fixation of these injuries. Previous studies have reported varying techniques for revision syndesmosis reconstruction, including screw fixation and tendon transfers.

We present the results of the use of the TightRope<sup>®</sup> suture for revision syndesmosis fixation. This implant has the advantage of maintaining physiological motion whilst allowing for healing of syndesmotic ligaments and prevents the need for further surgery to remove screws in already scarred soft tissues.

**Materials and methods:** We retrospectively analyzed 124 patients who required syndesmotic stabilization from January 2000 until December 2009. Eight of these 124 patients required surgical revision of their failed syndesmosis fixation, each of which was stabilized with the TightRope<sup>®</sup> Suture. All eight patients were followed up and their outcomes assessed. Seven of the eight patients in our study had technically sound initial fixation of the syndesmosis. Four of the eight patients had syndesmotic separation after screw removal 10 weeks after primary fixation.

**Results:** In our study, 6 of the 8 patients had good or satisfactory outcomes based on American Orthopedic Foot and Ankle Society (AOFAS) scores. In spite of accurate revision fixation of the syndesmosis, two patients required further surgery. One patient had conversion to an ankle fusion because of persistent syndesmotic widening and ongoing pain after revision surgery. Another patient required syndesmotic arthrodesis as a result of persistent pain.

**Conclusion:** TightRope<sup>®</sup> suture fixation is a good method of syndesmosis stabilization in patients requiring revision surgery. Randomized studies would be required to compare the effectiveness of this method of fixation with screw fixation.

**Keywords:** Ankle, Fracture, Revision, Syndesmosis, Tight rope.

**How to cite this article:** Rajagopalan S, Moonot P, Sangar A, Taylor H. Revision Ankle Syndesmosis Fixation: Functional Outcome after TightRope<sup>®</sup> Fixation. *J Foot Ankle Surg (Asia-Pacific)* 2016;3(1):23-27.

**Source of support:** Nil

**Conflict of interest:** None

<sup>1-4</sup>Orthopaedic Surgeon

<sup>1-4</sup>The Royal Bournemouth Hospital NHS Trust, Bournemouth UK

**Corresponding Author:** Pradeep Moonot, Orthopaedic Surgeon, The Royal Bournemouth Hospital NHS Trust Bournemouth, UK; e-mail: drmoonot@gmail.com

## INTRODUCTION

Syndesmotic disruptions are seen in 13% of all ankle fractures.<sup>1</sup> These require anatomical reduction to provide optimal functional outcome.<sup>2,3</sup> Malreduction of the syndesmosis has been reported to cause secondary arthritis and instability that is correlated with poor subjective and objective outcomes.<sup>2,4,5</sup> These injuries present a challenge in operative decision-making and reduction. Both while and whilst have been in the language for a very long time. While was in use in Old English; whilst is a Middle English development of while. As conjunctions they are interchangeable in meaning, but whilst has not survived in standard American English there are studies describing the outcome of malreduced syndesmotic injuries, there are very few studies that report the outcome after revision fixation of the syndesmosis.

We present the results of revision fixation of malreduced tibiofibular syndesmosis using the Ankle TightRope<sup>®</sup> (Arthrex). The TightRope is a low-profile system comprising a #5 fiberwire loop that is tensioned and secured between metallic buttons placed against the outer cortices of the tibia and fibula, providing physiological stabilization of the ankle mortise. To our knowledge, this is the first study to report the results of revision syndesmosis fixation using the Ankle TightRope<sup>®</sup>.

## MATERIALS AND METHODS

We retrospectively analyzed 124 patients who required syndesmotic stabilization from January 2000 until December 2009. Eight out of 124 of these patients required revision of the syndesmosis fixation.

In our series, the mean age of the eight patients at the time of revision surgery was 49 (23–85 years). The primary ankle injury in seven ankles was Weber C type fracture and in one ankle it was a Weber B type fracture. The average time for failure after primary stabilization was 8 weeks (4–14 weeks). All eight patients were followed for a mean duration of 21 months (7–46 months). Of the eight patients in our series, one had revision surgery because of technical intraoperative error, and seven had failure of fixation despite initial adequate fixation.

All measurements on radiographs were made 1 cm proximal to the ankle joint line. Failure was defined when the following criteria were met.

- Decrease in the tibiofibular overlap of < 10 mm in the anteroposterior (AP) view.<sup>6,7</sup>

- Increase in the tibiofibular clear space >5 mm in the AP view.<sup>6,7</sup>
- Tibiofibular overlap of <1 mm in the mortise view.<sup>7</sup>
- Associated pain in the ankle.

### Surgical Technique

A longitudinal incision was made over the lateral aspect of the lower third of the fibula. Previous syndesmotic screws were removed if present. A medial incision was made to expose the medial gutter and clear any interposed soft tissue. The anterior aspect of the tibiofibular joint was exposed, and under direct vision, a pelvic reduction clamp was applied to reduce the syndesmosis. Two Ankle TightRopes were inserted using standard techniques. External rotation stress test under fluoroscopy was used to confirm stability.

Postoperatively ankle mobilization was initiated from the second week and non-weight bearing status was maintained until 6 weeks. Patients were followed postoperatively at standardized time intervals of 3, 6, and 12 months for clinical and radiological assessment (AP, lateral, and mortise views).

Postoperative complications (wound infections and thromboembolic complications) and length of hospital stay were also recorded.

Functional evaluation was performed using the AOFAS scoring system. All revision syndesmosis fixations were carried out by the senior author (HT).

### Data Analysis

Patient demographics (age, gender), injury characteristics (mechanism of injury and displacement), American Society of Anesthesiologists (ASA) classification of operative risk, and co-morbidities of the patients were recorded (Table 1).

The fractures were classified based on Weber and Lauge–Hansen classification<sup>8</sup> and the presence of a posterior malleolar fracture was recorded.

### RESULTS

Of the eight patients, one patient was treated with revision of the fibular fixation along with syndesmotic fixation. Five patients had good results, one satisfactory, and two had poor outcomes. Case numbers 1, 2, 3, 4, and 6 had good results (Fig. 3).

The mean AOFAS score improved from 56 preoperatively to 78 at 12 months postoperatively.

*Case number 5* had persistent pain in the ankle. Magnetic resonance imaging of the ankle showed talar dome osteochondral defect. He settled well with a single dose of steroid injection in the ankle and is currently symptom free.

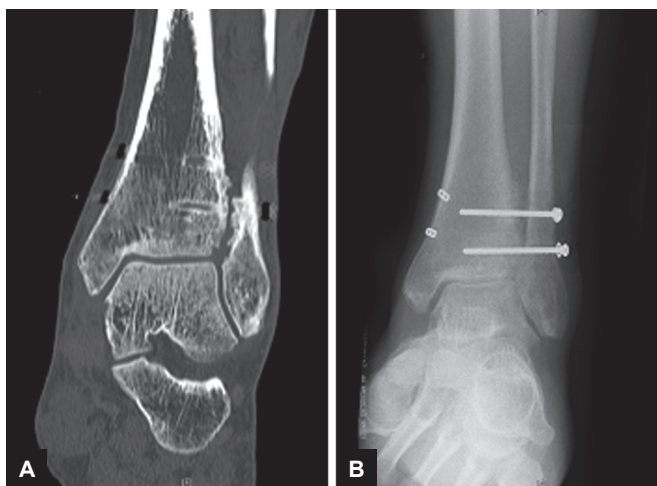
*Case number 6:* This patient developed ankle pain at 4 months follow-up with increase in the medial clear space and tibiofibular space. An ankle fusion was performed at 5 months.

*Case number 7:* This patient had recurrent pain in the ankle and MRI showed evidence of distal tibial osteonecrosis secondary to posterior capsular avulsion. Fluoroscopic-guided drilling of the distal tibia was undertaken, which improved his symptoms. However, he had persistent pain and has subsequently gone on to have distal tibiofibular fusion. He is currently bearing full weight comfortably (Figs 2A and 2B).

*Case number 8:* One ankle developed deep-seated infection, which required open debridement on two occasions. The Tightrope<sup>®</sup> was removed at 3 months post-revision surgery. Currently, she has pain-free ankle movements at 6 months follow-up from her revision surgery (Figs 1A and B).

**Table 1:** American society of anesthesiologists classification of operative risk, and co-morbidities

Case no.	Age	Gender	Mode of primary injury	ASA grade	Co-morbidities	Type of injury	Type of primary fixation	Time to failure after primary fixation
1	23	F	RTA	1	Nil	Weber C Pronation external rotation	One tricortical screw fixation	2 weeks
2	29	M	Fall while running	1	Nil	Pronation external rotation	Lat 1/3d tubular plate Two tricortical screw	14 weeks
3	37	F	Fall on high heels	1	Depression	Weber C Pronation external rotation	Medial malleolar fixation One tricortical screw	Intraoperative error
4	57	F	Fall	1	Nil	Weber B Supination external rotation	Two tricortical screw	12 weeks
5	59	M	Fall whilst walking	2	Smoker	Weber C Pronation external rotation	One tricortical screw	6 weeks
6	84	F	Fall on ice	2	HT Hyperlipidemia	Weber C Pronation Abduction	Lat 1/3d tubular plate Two tricortical screw	12 weeks
7	55	M	Fall while walking	1	Nil	Weber C Pronation external rotation	Two tricortical screw	6 weeks
8	44	F	Fall onto the floor	2	Smoker	Weber C Pronation external rotation	Two tricortical screw	12 weeks



**Figs 1A and B:** (A) Radiographs showing syndesmosis incongruity in spite of TightRope fixation; and (B) tibiofibular fusion

## DISCUSSION

It has been demonstrated that 13% of all ankle fractures and 20% of all operative ankle fractures have a disrupted syndesmosis.<sup>1</sup> Complete disruption of the syndesmosis combined with a tear of the deltoid ligament causes a decrease of 40% in the tibiotalar contact area and an increase in 36% contact pressure.<sup>3</sup>

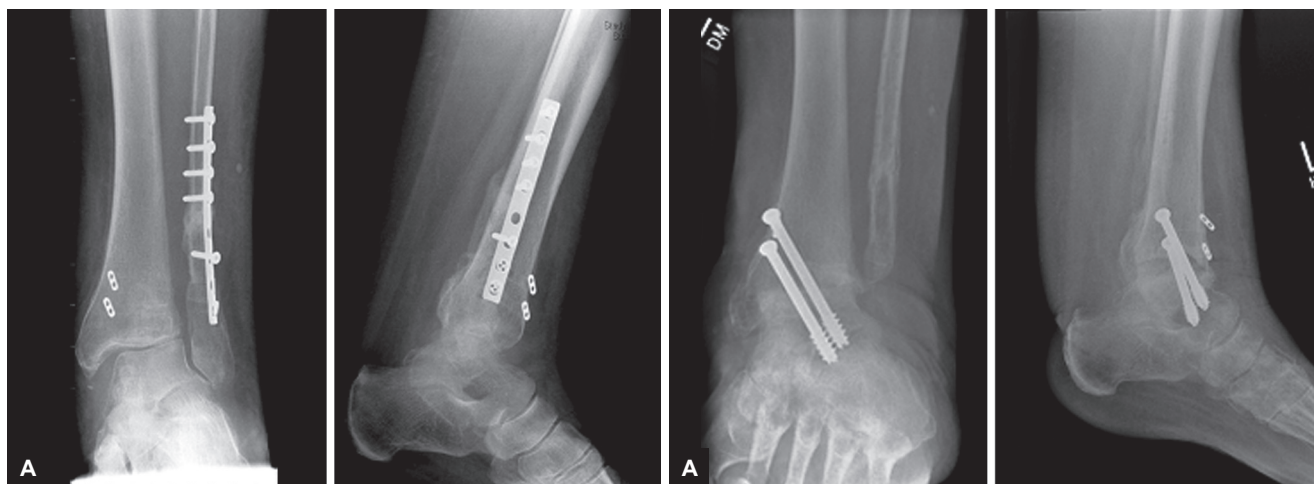
Ankle fractures involving the syndesmosis require anatomical reduction to provide optimal functional outcome.<sup>2,3</sup> Syndesmotic injuries present a challenge in operative decision-making and reduction. Malreduction of the syndesmosis has been reported to cause late arthritis and instability that is correlated with poor subjective and objective outcomes.<sup>1,4,5</sup> Weening and Bhandari<sup>9</sup> found that the only significant predictor of functional outcome was reduction of the syndesmosis despite the variability in technique of fixation. In a study by Egol et al,<sup>10</sup> poorer outcomes were observed at 1-year follow-up compared with patients who had malleolar fixation alone. A significant association between syndesmotic malreduction and

poor subjective and objective outcomes was also reported by Kennedy et al.<sup>11</sup>

Although the literature is replete with studies involving syndesmosis, there are very few studies that have looked into revision syndesmosis fixation. Harper<sup>12</sup> reported results on definitive refixation and stabilization of chronic persistently widened syndesmosis in six cases. The revision fixation was carried out using one or two large cannulated screws engaging four cortices in all cases except one. Four out of six patients reported satisfactory results at 12-month follow-up. One patient required syndesmosis fusion because of persistent residual incongruity and associated pain. Beals and Manofi described a case of late syndesmotic reconstruction using cancellous screw and reported excellent outcome.<sup>13</sup> Bone graft was used to fix through holes in the tibia and fibula by Outland.<sup>14</sup> Castaing et al performed reconstruction of the anterior and posterior tibiofibular ligament with peroneus brevis tendon for late syndesmotic instability. Grass et al<sup>15</sup> reported good results using peroneus longus ligamentoplasty in chronic instability of the tibiofibular syndesmosis. In our study, 6 out of 8 patients had good to satisfactory outcome following the use of Ankle TightRope. In spite of accurate revision fixation of the syndesmosis, two patients had to have further revision surgeries. One patient had ankle fusion because of persistent widening of the syndesmosis after revision surgery. Another patient required tibiofibular fusion as he had a persistently painful syndesmosis. He is currently pain free.

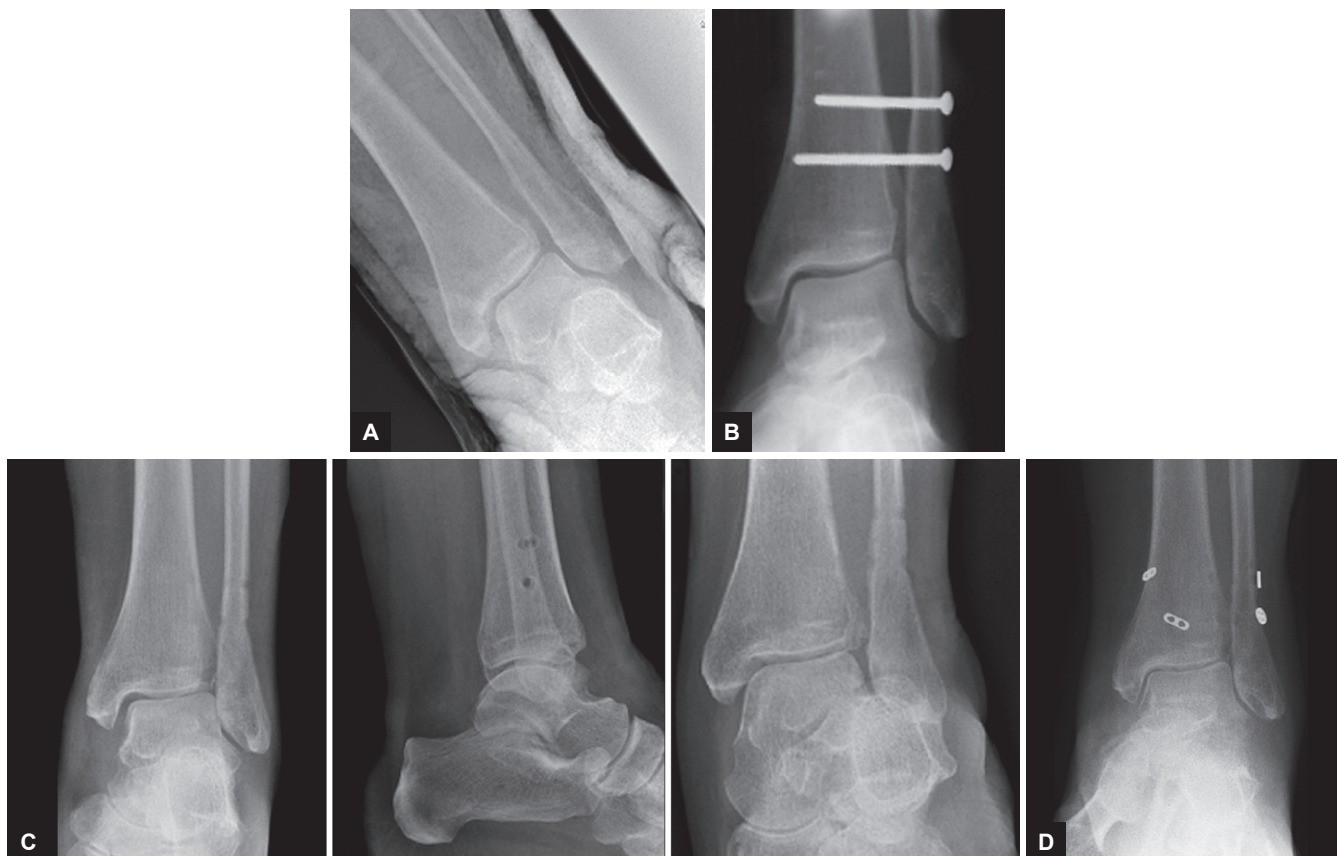The limitations of our study are its retrospective nature and limited sample size. Our study did not have any comparable controls and had limited period of follow-up.

Ankle TightRope has been used as an alternative for primary syndesmosis fixation. In a study by Cottom et al,<sup>16</sup> intraosseus fixation with endobutton resulted in comparable results in terms of subjective score compared with traditional primary syndesmosis screw fixation. The



**Figs 2A and B:** (A) Failure after TightRope fixation; and (B) for failed syndesmosis fixation





**Figs 3A to D:** (A) Preoperative radiograph of ankle showing syndesmosic injury; (B) syndesmosis fixation with two screws; (C) stress external rotation view after removal of the screws; and (D) six months post revision syndesmosic fixation

advantage of suture button construct when compared with screw fixation system is the ability to resist diastasis and also to maintain physiological movement of the fibula in relation to the tibia when the ankle is subjected to external rotation or axial loading.<sup>17</sup>

Functional outcomes were improvements in fractured, loosened, or removed screws compared with those with intact syndesmosis screws. This further adds to the point that the syndesmosis must be fixed using suture button fixation to preserve syndesmosis movement while allowing healing.<sup>18</sup> Removal of the syndesmosis screw involves a second surgery, and incision into an incompletely healed wound may contribute to higher rates of infection.<sup>19</sup>

All patients in our study except one had technically sound initial fixation of syndesmosis. One patient who had technically incorrect fixation (case 2) required re-fixation to lengthen the fibula to correct length and had syndesmosis fixation using Ankle TightRope. Four out of eight of our patients had syndesmosic separation after screw removal 10 weeks after primary fixation. We advocate intraoperative stress radiographs of the syndesmosis during removal of syndesmosis screw. We also advocate the use of direct visualization and reduction of the syndesmosis, particularly in the revision situation as this allows for accurate reduction of the syndesmosis

as shown by Miller et al.<sup>20</sup> As a result of this study, it has become our routine practice to reduce the syndesmosis by direct visualization before fixation, for both primary and revision cases.

Our study demonstrates that syndesmosic injuries are difficult to treat and that even with technically correct fixation failure of the syndesmosis in the post-operative period can occur. Ankle TightRope is a viable alternative that can be used in revision syndesmosis fixation. This has the advantage of preventing further surgery to remove screws in already scarred soft tissues. Ankle TightRope also maintains physiological motion whilst allowing for healing of syndesmosic ligaments.

## CONCLUSION

Ankle TightRope is a good method of fixation in patients who require revision syndesmosis fixation. Randomized studies are required to further elucidate the effectiveness of this method of fixation compared with screws.

## REFERENCES

1. Van Staa TP, Dennison EM, Leufkens HG, Cooper C. Epidemiology of fractures in England and Wales. *Bone* 2001 Dec;29(6): 517-522.

2. Leeds HC, Ehrlich MG. Instability of the distal tibiofibular syndesmosis after bimalleolar and trimalleolar ankle fractures. *J Bone Joint Surg Am* 1984 Apr;66(4):490-503.
3. Ramsey PL, Hamilton W. Changes in tibiotalar area of contact caused by lateral talar shift. *J Bone Joint Surg Am* 1976 Apr;58(3):356-357.
4. BodenSD, Labropoulos PA, McCowin P, Lestini WF, Hurwitz SR. Mechanical considerations for the syndesmosis screw. A cadaver study. *J Bone Joint Surg Am* 1989 Dec;71(10):1548-1555.
5. Chissell HR, Jones J. The influence of a diastasis screw on the outcome of Weber type-C ankle fractures. *J Bone Joint Surg Br* 1995 May;77(3):435-438.
6. Harper MC. An anatomic and radiographic investigation of the tibiofibular clear space. *Foot Ankle* 1993 Oct;14(8):455-458.
7. Petrone FA, Gail M, Pee D, Fitzpatrick T, Van Herpe LB. Quantitative criteria for prediction of the results after displaced fracture of the ankle. *J Bone Joint Surg Am* 1983 Jun;65(5):667-677.
8. Lauge-Hansen N. Fractures of the ankle. II. Combined experimental-surgical and experimental-roentgenologic investigations. *Arch Surg* 1950 May;60(5):957-985.
9. Weening B, Bhandari M. Predictors of functional outcome following transsyndesmotom screw fixation of ankle fractures. *J Orthop Trauma* 2005 Feb;19(2):102-108.
10. Egol KA, Pahk B, Walsh M, Tejwani NC, Davidovitch RI, Koval KJ. Outcome after unstable ankle fracture effect of syndesmotom stabilisation. *J Orthop Trauma* 2010 Jan;24(1):7-11.
11. Kennedy JG, Softe KE, Dalla Vedova P, Stephens MM, O'Brien T, Walsh MG, McManus F. Evaluation of the syndesmotom screw in low Weber C ankle fractures. *J Orthop Trauma* 2000 Jun-Jul;14(5):359-366.
12. Harper MC. Delayed reduction and stabilization of tibiofibular syndesmosis. *Foot Ankle Int* 2001 Jan;22(1):15-18.
13. Beals TC, Manofi A. Late syndesmosis reconstruction: a case report. *Foot Ankle Int* 1998 Jul;19(7):485-488.
14. Outland T. Sprains and separations of the inferior tibiofibular joint without important fracture. *Am J Surg* 1943 Feb;59(2):320-329.
15. Grass R, Rammelt S, Biewener A, Zwipp H. Peroneus longus ligamentoplasty for chronic instability of the distal tibiofibular syndesmosis. *Foot Ankle Int* 2003 May;24(5):392-397.
16. Cotton JM, Hyer CF, Philbin TM, Berlet GC. Transosseous fixation of syndesmosis: comparison of suture endobutton to screw fixation in 50 cases. *J Foot Ankle Surg* 2009 Nov-Dec;48(6):620-630.
17. Klitzman R, Zhao H, Zhang LQ, Strohmeyer G, Vora A. Suture-button versus screw fixation of the syndesmosis: a biomechanical analysis. *Foot Ankle Int* 2010 Jan;31(1):69-75.
18. Manjoo A, Sanders DW, Tieszer C, MacLeod MD. Functional and radiographic results of patients with syndesmotom screw fixation: implications for screw removal. *J Orthop Trauma* 2010 Jan;24(1):2-6.
19. Sinisaari I, Pätäälä H, Böstman O, Mäkelä EA, Hirvensalo E, Partio EK, Törmälä P, Rokkanen P. Metallic or absorbable implants for ankle fractures a comparative study of infections in 3111 cases. *Acta Orthop Scand* 1996 Feb;67(1):16-18.
20. Miller AN, Carroll EA, Parker RJ, Boraiah S, Helfet DL, Lorich DG. Direct visualisation for syndesmotom stabilisation of ankle fractures. *Foot Ankle Int* 2009 May;30(5):419-426.