

Subcutaneous Foot Phaeohyphomycosis due to *Alternaria alternata*

¹Mithun Shrinivas Jakkan, ²Vikas Madhav Agashe, ³Rajeev Soman, ⁴Alan Almeda

ABSTRACT

Alternaria alternata, a saprophytic pigmented fungus, usually manifests in immunocompromised hosts. A case of 53-year-old male who underwent renal transplant 4 years back with recurrent foot swelling and previously misdiagnosed and treated for actinomycosis is presented. The swelling was completely excised, staining and culture diagnosed it to be *Alternaria alternata* infection which responded very well to oral voriconazole.

Keywords: Phaeohyphomycosis, *A. alternata*, Voriconazole.

Abbreviations: ITS: Internal transcribed spacer, MIC: Minimum inhibitory concentration.

How to cite this article: Jakkan MS, Agashe VM, Soman R, Almeda A. Subcutaneous Foot Phaeohyphomycosis due to *Alternaria alternata*. J Foot Ankle Surg (Asia-Pacific) 2015;2(1):44-46.

Source of support: Nil

Conflict of interest: None

INTRODUCTION

Phaeohyphomycosis refers to a subcutaneous and systemic infection caused by dark walled dematiaceous fungi.^{1,2} Infection with more than 100 species and 60 genera of fungi has been reported over the past several decades and *Alternaria* species is one of the common etiologic agents among them.¹⁻⁴ Among this genus, *Alternaria alternata* is the most common fungi.² *Alternaria* species are common saprobes found on plant remains, in soils or in other substrata, and despite its ubiquitous presence worldwide, its infection is rare.^{5,6} These are opportunistic fungi and infection tend to occur in high risk patients, such as patients undergoing immunosuppressive therapy (continuation phase), bone marrow or solid organ transplant, acquired immunodeficiency syndrome, cushing disease, hematologic malignant

disease.^{2,3,7-9} Phaeohyphomycosis exhibits a variety of clinical presentations, ranging from solitary subcutaneous nodule to fulminant disseminated disease.^{1,3,7} This report describes a chronic recurrent foot swelling with *A. alternata* infection.

CASE REPORT

A 53-year-old male presented with complaints of recurrent swelling and mild pain over the base of second toe of left foot since 1 year. There was no history recurrent fever, injury, thorn prick, discharging sinus over the left foot. Patient has undergone renal transplantation 4 years ago and was on immunosuppressive drugs like deflazocort 6 mg twice a day, mycophenolate mofetil 500 mg twice a day. Excision biopsy of the foot swelling was done elsewhere ten months ago and histopathological diagnosis made was Actinomycosis with no growth on culture. He took tablet doxycycline for 3 months, but the swelling had recurred in matter of 2 months. The swelling at presentation was solitary, mildly tender, soft to firm, irregular shaped, partly adherent to overlying skin with no signs of inflammation (Fig. 1). After laboratory and radiological investigations, we planned for excision biopsy. Under spinal anesthesia, tourniquet was applied. Lazy S shaped incision was taken over plantar surface of swelling extending into first web space. Blackish, soft, irregular shaped mass partly adherent to skin extending into dorsal surface through 1st web space was excised (Fig. 2). Incision could not be completely closed because of the skin excision, hence partly left open after

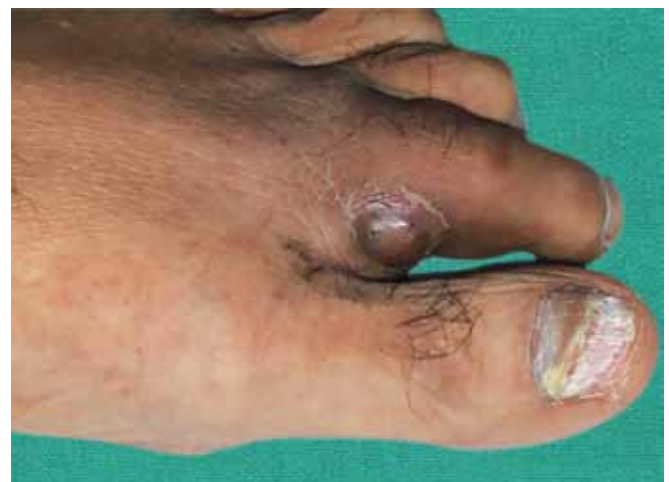

Fig. 1: Clinical image of left foot

¹Clinical Research Fellow, ²Consultant, ^{3,4}Senior Consultant

^{1,2}Department of Orthopedics, PD Hinduja Hospital and Research Center, Mumbai, Maharashtra, India

³Department of Internal Medicine, PD Hinduja Hospital and Research Center, Mumbai, Maharashtra, India

⁴Department of Nephrology, PD Hinduja Hospital and Research Center, Mumbai, Maharashtra, India

Corresponding Author: Mithun Shrinivas Jakkan, Clinical Research Fellow, Department of Orthopedics, PD Hinduja Hospital and Research Center, Mumbai, Maharashtra, India
Phone: 02224449199, e-mail: mithunjakkan@gmail.com

achieving hemostasis. Microscopy showed several colonies of pigmented fungus in dermal and subcutaneous tissue with dense granulomatous inflammation and necrosis surrounding these colonies. The staining and culture grown in Sabouraud's agar showed the fungus *A. alternata* (Fig. 3). Tablet voriconazole 400 mg twice a day on day 1 followed by 200 mg twice a day was started and continued for 6 months. The wound healed by secondary intention without any surgical intervention (Fig. 4). Patient was asymptomatic after regular monthly follow-up and after the completion of 6 months course of tablet voriconazole (Fig. 5). Immunosuppressive therapy is continued.

DISCUSSION

Aiello coined the term 'phaeohyphomycosis' in 1974.¹⁰ The distinctive characteristic of the causative group is due to presence melanin pigmentation in their cell wall which has been implicated as a virulence factor which is pathogenic even to immunocompetent host.^{7,11} The melanin acts as a scavenger of free radical and hypochlorite and inhibits enzyme production by phagocytic cells.⁷ The incidence of fungal infection after solid organ transplantation ranges from 5% among recipients of kidney to 40% among liver recipients.⁷ The incidence rate of phaeohyphomycosis increased from 1.0 to 3.1 cases per 100,00 patient-days during the study period from 1989 to 2008.¹² The published literature contains 210 reported cases of human alternarioses from 1933 to 2008, with skin and subcutaneous (74.3%), oculomycosis (9.5%), rhinosinusitis (8.1%) and onychomycosis (8.1%).⁹ Male predominance in occurrence of infection, suggesting occupational risk for this disease.^{7,9}

Mode of transmission: Skin infections are either by exogenous traumatic inoculation or colonization of altered skin, or via systemic spread with secondary cutaneous involvement. The previous mode being more common, lesions are mostly observed on the extremities.^{5,7} Inhalation is also the source for transmission.^{7,8} In our case, mode of transmission could not be identified.

Laboratory diagnosis includes isolation of fungal hyphae on potassium hydroxide mount and culture on Sabouraud's agar, potato dextrose agar.^{3,10} Morphologically, the pigmented hyphae and conidia should be well-identified.³ The conidia of *A. alternata* are medium brown with short, cylindrical beak with profusely branched chain.⁹ The other stains performed on tissues for light microscopy examination are Hematoxylin-eosin, Grocott-Gomori and Fontana-Masson standard methods.¹⁰ The identification on the basis of morphology can be confirmed by sequencing of rDNA ITS domain.^{5,13}

Surgical excision of the accessible lesion in combination of antifungal therapy is the effective treatment of choice for subcutaneous alternarial infections.⁷ The antimycotic drugs used are amphotericin B, itraconazole.^{1,5,7,12,14} Marilia Marufuji Ogawa et al 2009 presented a case series of prospective follow-up of 17 kidney transplant patient treated for subcutaneous phaeohyphomycosis and they found poor response or hepatotoxicity to itraconazole in severe disease cases.⁷ Voriconazole,

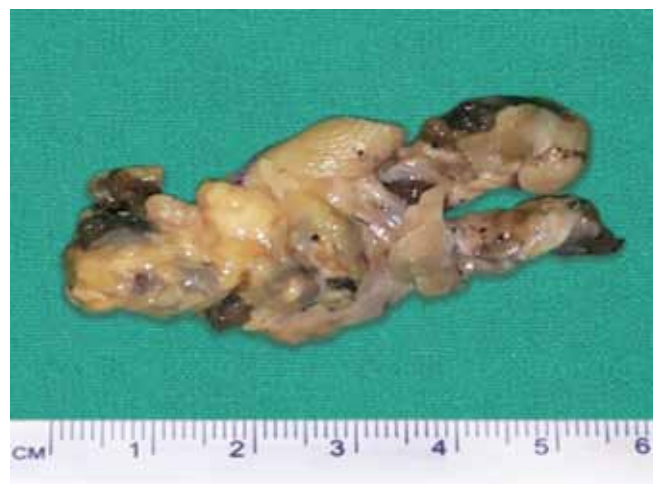

Fig. 2: Blackish mass partly adherent to skin

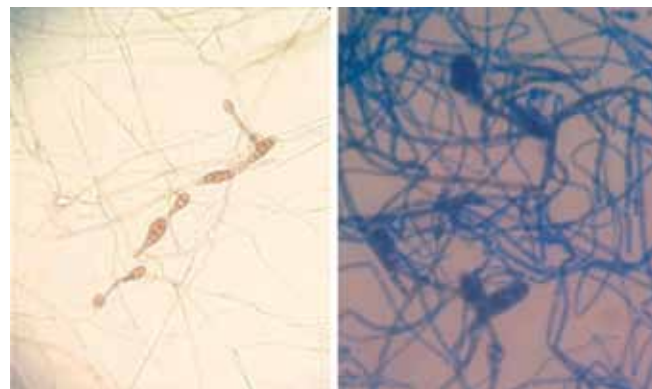


Fig. 3: Microscopic images of *Alternaria alternata*

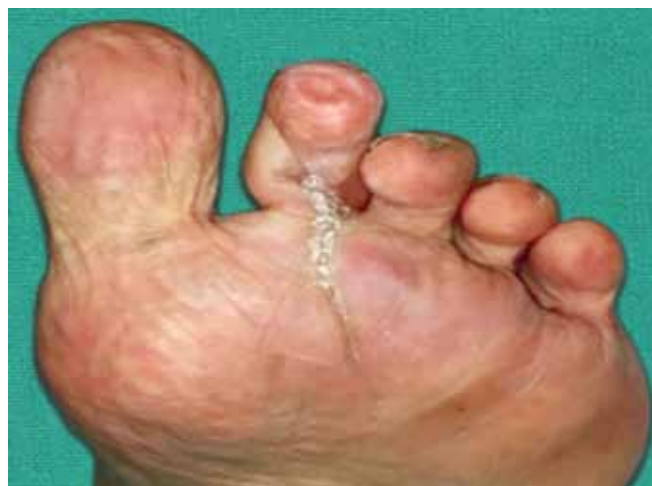
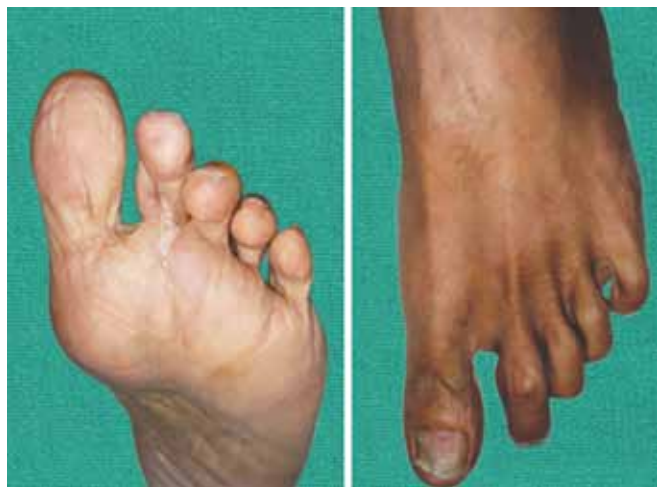
Fig. 4: Healed wound at 2 months of treatment

Table 1: Factors considered for using antifungal agents

Drugs	<i>Alternaria</i>	Bone	CNS	Use with renal dysfunction	Interactions
Voriconazole	Yes MIC lower than that of Itraconazole Wildfeuer A Mycoses 1998;41:309-19 ¹⁶	Yes	Yes		Absorption more predictable
Itraconazole	Yes	Yes	–	Yes	If absorption is erratic from the tablets, its adjustment is difficult
Fluconazole	–	–	Yes	Yes	
Terbinafine	Yes	Yes	–	Not suitable if creatinine clearance is <10	

CNS: Central nervous system

**Fig. 5:** After completion of 6 months of treatment

derivative of fluconazole, with broad spectrum of activity is a novel alternative to itraconazole in treatment of *Alternaria* infection.^{2,9,15} Marilia Marufuji Ogawa, MD et al recommend antifungal therapy for duration of 6 months for effective treatment.⁷ RC Boyce et al⁶ mentioned about the duration of antifungal treatment should be individualized with ranging from 3 to 4 months to 1 year. In our case, duration of treatment was 6 months with complete remission. The final impact of phaeohyphomycosis due to alternarial infection on renal allograft is minimal.⁷

The factors were considered in planning anti-fungal treatment in this case (Table 1).¹⁶

CONCLUSION

Subcutaneous phaeohyphomycosis due to *A. alternata* infection though rare, should be considered as a differential diagnosis in solid organ transplant recipient who is on immunosuppressive therapy.

REFERENCES

- Halaby T, Boots H, Vermeulen A, Beguin H. Phaeohyphomycosis caused by *alternaria* infectoria in a renal transplant recipient. *J Clin Microbiol* 2001 May;39(5):1952.
- Gomes J, Vilarinho C, da Luz Duarte M, Brito C. Cutaneous phaeohyphomycosis caused by *alternaria alternata*: case

report. *Case Reports in Dermatological Medicine* 2011 Article ID 385803.

- Larsen CG, Maiken CA, Elizabeth K, Micheal P, Soren T, Frederik. Subcutaneous phaeohyphomycosis in a renal transplant recipient successfully treated with voriconazole. *Acta Dermato-Venerologica* 2009;89(6):657-658.
- Kathiah R, Kumar S, Sundaram KM, Rajalakshmi V. Phaeohyphomycosis, emerging as a common cause of diagnostic dilemmas. *Int J Med Health Sci* 2014 Apr;3(2):150-152.
- Mayser P, Nilles M, de Hoog GS. Cutaneous phaeohyphomycosis due to *alternaria alternata*: case report. *Mycoses* 2002 Oct;45(8):338-340.
- Boyce RD. Phaeohyphomycosis due to *alternaria* species in transplant recipients. *Transpl Infect Dis* 2010 Jun;12(3):242-250.
- Ogawa MM, Galante NZ, Godoy P, Fischman-Gompertz O, Martelli F, Colombo AL, Tominori J, Medinor-Pestana JO. Treatment of subcutaneous phaeohyphomycosis and prospective follow-up of 17 kidney transplant recipients. *J Am Acad Dermatol* 2009 Dec;61(6):977-985.
- Langfelder K, Streibel M, Jahn B, Haase G, Brakhage AA. Biosynthesis of fungal melanins and their importance for human pathogenic fungi. *Fung Genet Biol* 2003 Mar;38(2):143-158.
- Pastor FJ, Guarro J. *Alternaria* infections: laboratory diagnosis and relevant clinical features. *Clin Microbiol Infect* 2008 Aug;14(8):734-746.
- Shirbur SN, Telkar SR, Goudar BV, Mathew T. Recurrent phaeohyphomycosis: a case report. *J Clin Diagn Res* 2013 Sep;7(9):2015-2016.
- Gurcan S, Piskin S, Kilic H, Temelli BA, Yalcin O. Cutaneous infection caused by *alternaria alternata* in an immunocompetent host. *Mikrobiyol Bul* 2009 Jan;43(1):163-167.
- Ben-Ami R, Lewis RE, Raad II, Kontoyiannis DP. Phaeohyphomycosis in tertiary care cancer center. *Clin Infect Dis* 2009 Apr;48(8):1033-1041.
- de Hoog GS, Horre R. Molecular taxonomy of the *alternaria* and *Ulocladium* species from humans and their identification in routine laboratory. *Mycoses* 2002 Oct;45(8):259-276.
- Revankar SG. Phaeohyphomycosis. *Infect Dis Clin North Am* 2006 Sep;20(3):609-620.
- Purkins L, Wood N, Ghahramani P, Greenhalgh K, Allen MJ, Kleinermans D. Pharmacokinetics and safety of voriconazole following intravenous- to oral-dose escalation regimens. *Antimicrob Agents Chemother* 2002;46(8):2546-2553.
- Wildfeuer A, Seidl HP, Paule I, Haberreiter A. In vitro evaluation of voriconazole against clinical isolates of yeasts, moulds and dermatophytes in comparison with itraconazole, ketoconazole, amphotericin B and griseofulvin. *Mycoses* 1998 Sep-Oct;41(7-8):309-319.