

Nontraumatic Osteochondral Lesion of the Talar Head: A Case Report and Description of Operative Technique for Arthroscopic Debridement

¹J Mangwani, ²A Patel, ³W Al-Jundi, ⁴A Askari, ⁵D Moore

ABSTRACT

Osteochondral lesions of the talar dome are well described. To our knowledge, there are no published reports of osteochondral lesion of the talar head. We report the case of a 16-year-old girl who presented with a nontraumatic osteochondral lesion of talar head, which was treated with arthroscopic debridement and bone marrow stimulation. At 6-month follow-up, the patient was symptom free and the radiograph showed signs of healing of the lesion.

Keywords: Osteochondral lesion, Talar head, Arthroscopy, Debridement.

How to cite this article: Mangwani J, Patel A, Al-Jundi W, Askari A, Moore D. Nontraumatic Osteochondral Lesion of the Talar Head: A Case Report and Description of Operative Technique for Arthroscopic Debridement. *J Foot Ankle Surg (Asia-Pacific)* 2014;1(1):34-37.

Source of support: Nil

Conflict of interest: None

INTRODUCTION

An osteochondral lesion is an injury, small fracture or significant defect in the cartilage surface of a joint.¹ These lesions most often affect the knee, followed by the elbow and the talus. Lesions of the talus account for 4% of all osteochondral lesions in the body.²

A history of trauma is present in more than 85% of patients.^{3,4} Although a traumatic etiology is believed to play a major role in production of these lesions, idiopathic

osteonecrosis has also been reported. Kappis et al⁵ believed that the lesions were the result of ischemic necrosis of the underlying subchondral bone that eventually led to separation of the fragment and its overlying articular cartilage. Non-traumatic lesions can also be familial. Multiple lesions can occur in the same patient, and identical medial talar dome lesions have been reported in identical twins.⁶

Diagnosing an osteochondral lesion is very difficult on physical examination. There is debate as to which adjunct investigation is best for diagnosing an osteochondral lesion. On conventional radiographs, osteochondral lesions may be missed. Magnetic resonance imaging (MRI) is better in cases of pure cartilage damage or for superficial lesions while CT is better for cystic lesions and lesions that involve both cartilage and bone injury. MRI correlates best with the surgical staging.

Treatment of osteochondral lesions includes conservative and surgical options; influenced by the various staging and grading systems. The current staging systems in use are for lesions of the talar dome rather than the talar head. We report a 16-year-old patient with an osteochondral lesion of the talar head who underwent arthroscopic debridement and bone marrow stimulation. A brief description of operative technique for talonavicular joint arthroscopy is also presented.

CASE REPORT

A 16-year-old girl presented with 3 months history of worsening sharp dorsomedial right ankle pain with intermittent swelling. There was no history of trauma to her foot and ankle. She smoked approximately 10 cigarettes per day from the age of 14 and had no other significant social, past medical, drug or family history.

On examination, she had an antalgic gait. There was no obvious swelling. She was tender over the anteromedial corner of the ankle joint and dorsal aspect of the talonavicular joint. Movements of the ankle joint were normal. Rest of the foot and ankle examination was essentially normal. The neurovascular status was normal.

Radiographs of the foot showed irregularity of talar head (Fig. 1). Blood tests for inflammatory markers were normal. Magnetic resonance imaging of her foot showed

^{1,5}Consultant, ²Senior Registrar, ³Specialist Registrar
⁴Surgical Research Fellow

¹Department of Trauma and Orthopedics, University Hospital of Leicester, Leicester, United Kingdom

²Department of Trauma and Orthopedics, St Marys and Charing Cross Hospitals, Imperial NHS Trust, London United Kingdom

³Department of Trauma and Orthopedics, Sheffield Vascular Institute, Northern General Hospital, Sheffield, United Kingdom

^{4,5}Department of Trauma and Orthopedics, Colchester Hospital University, NHS Foundation Trust, United Kingdom

Corresponding Author: J Mangwani, Consultant, Department of Trauma and Orthopedics, University Hospital of Leicester LE1 5WW, Leicester, United Kingdom, e-mail: jitendra.mangwani@uhl-tr.nhs.uk

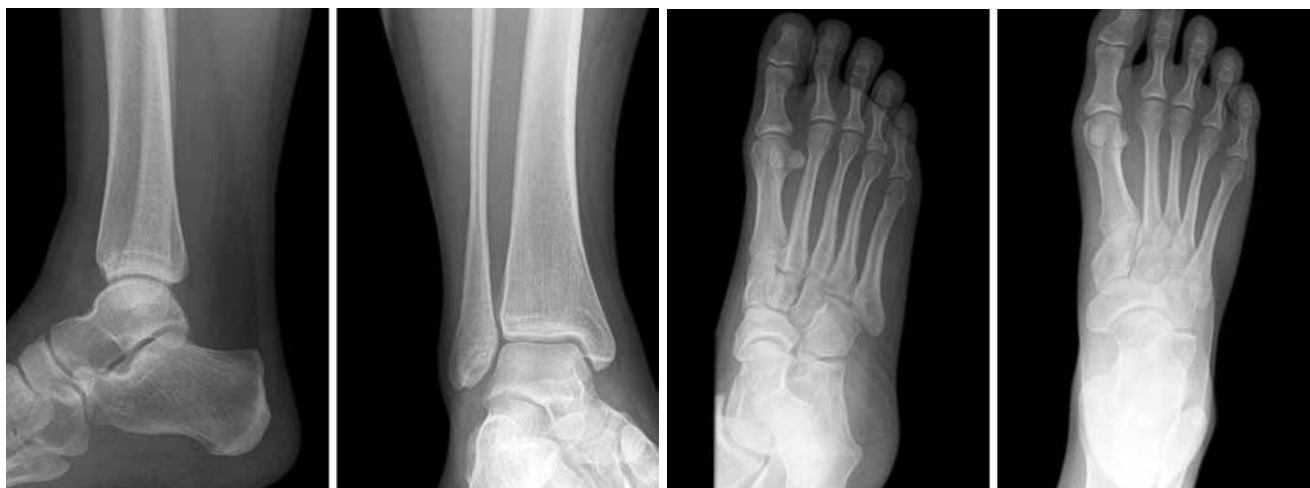

Fig. 1: Preoperative plain radiographs of patient's right foot and ankle showing some irregularity of the talar head

marked marrow edema in the anterior half of the talus with an osteochondral lesion of the talar head (Fig. 2). She was treated with arthroscopic debridement and bone marrow stimulation of the lesion after failed nonoperative treatment. She was mobilized toe-touch weight-bearing for the first 4 weeks, followed by building up to full weight bearing in an aircast boot for another 2 weeks. At 6 week postoperative follow-up, the patient had portal scar sensitivity and an abnormal sensation in the deep peroneal nerve distribution. This subsequently resolved spontaneously. At 6 months follow-up, she had complete resolution of symptoms and the repeat radiographs were normal.

OPERATIVE TECHNIQUE FOR ARTHROSCOPIC DEBRIDEMENT OF TALONAVICULAR OSTEOCHONDRAL LESION

Arthroscopy of the talonavicular joint was performed under general anesthetic and thigh tourniquet. A dorsomedial arthroscopic portal to the talonavicular joint was used (Fig. 3). The dorsomedial side of the talar head immediately proximal to the navicular was located. The image intensifier was used to confirm the position of the talus and navicular bones. Kirschner wires (2 mm) were inserted into the dorsomedial aspects of the talus and navicular under image intensifier guidance and the joint was distracted using a Hintegra distractor to allow adequate access for arthroscopy (Fig. 4).

A 5 mm incision was made over the dorsomedial aspect of the talonavicular joint and the arthroscope was inserted taking care to avoid local neurovascular structures and extensor tendons. The exact position of the osteochondral lesion was located on the joint surface of the talar head.

Arthroscopy revealed a grade 3 (Pritsch staging)/grade D (Cheng staging) lesion. Second portal was made over the talonavicular joint dorsolaterally. The lesion was debrided to underlying bleeding bone, which was also drilled

with K-wire (Fig. 5). The skin was closed with absorbable sutures and a heavy dressing was applied.

DISCUSSION

The treatment of osteochondral lesions can be conservative or surgical. Conservative treatment includes restricted

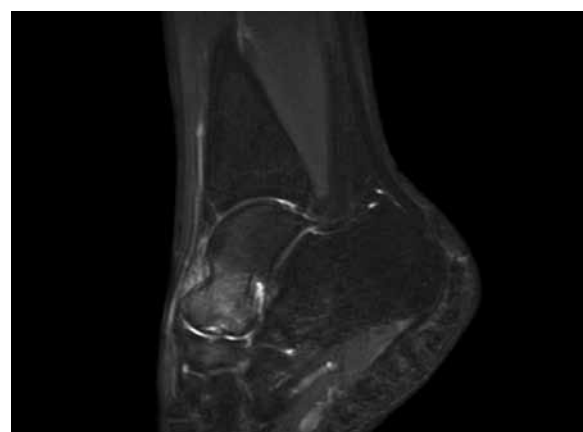

Fig. 2: Preoperative sagittal T2-weighted image of the right ankle with osteochondral lesion of talar head

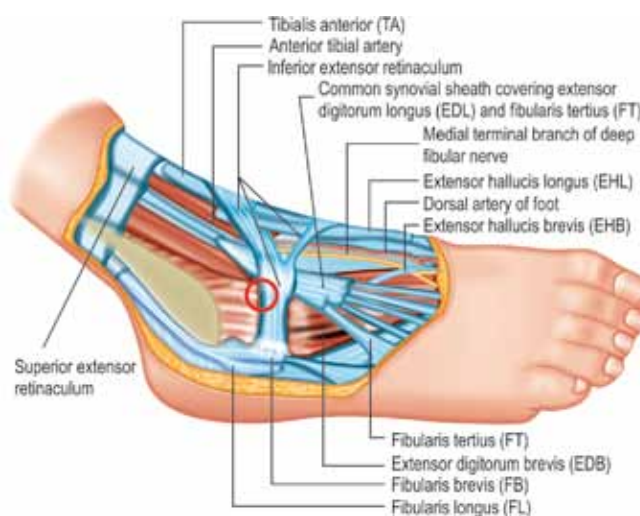


Fig. 3: Anatomy of the ankle and the site of insertion of the dorsolateral portal (circled) during arthroscopy¹⁰




Fig. 4: Intraoperative fluoroscopy images showing distraction of the TN joint and drilling of the osteochondral lesion

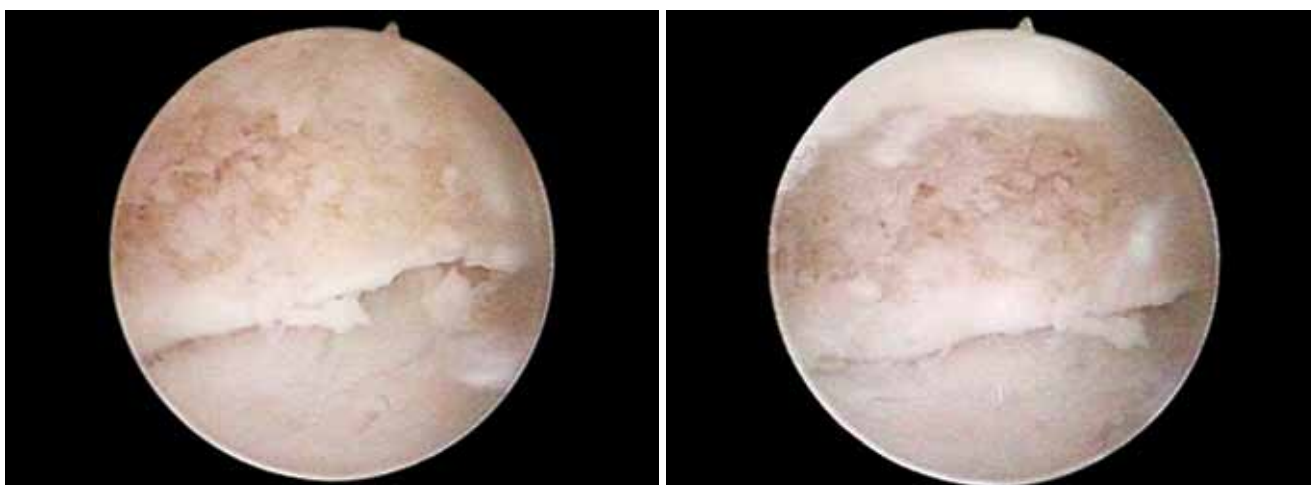

Fig. 5: Postdebridement intraoperative arthroscopy images of an osteochondral lesion of the talar head

activity, immobilization or physiotherapy and may initially be attempted in low-grade lesions.⁷ There is no firm evidence that nonweight-bearing cast immobilization offers improved results over weight bearing casts. However, studies have shown that a trial of conservative treatment has no adverse effect on subsequent surgical intervention.⁸

Symptomatic and high-grade lesions are indications for operative intervention. Such symptoms include effusion, catching or locking of the ankle, instability preceded by pain, and ankle pain relieved with diagnostic lignocaine⁵ Surgical options vary according to the size, depth and amount of damage associated with an osteochondral lesion. Patient characteristics, such as age, degenerative change and level of activity should also be considered.

Surgical treatment can be divided in two groups, non-tissue transplantation and tissue transplantation.¹⁰ Nontissue transplantation methods include internal fixation of loose fragments or arthroscopy (excision, curettage, drilling, microfracture). A study conducted by Robinson et al (2003)⁹, showed significant improvement with arthroscopic treatment in MRI grade I-IV osteochondral talar dome lesions.

Tissue Transplantation modalities include autologous bone grafting, autologous chondrocyte transplantation, osteochondral autograft transplantation (OATs) and osteochondral allograft transplantation.

The most common surgical procedure for an osteochondral lesion of the talar dome is arthroscopic exploration and debridement.¹ The arthroscopic approach varies depending on the location of the lesion. The lesion and all nonviable articular cartilage should be removed. The subchondral bone should be fenestrated with either a K-wire or a chondral pick. The outcome becomes less favorable as the size of the lesion and, more importantly, the depth of the lesion increases. In general, the guideline for a cut off for drilling options is a lesion less than 1 cm in diameter and a lesion less than 0.5 cm in depth.¹ Whether or not these figures can be applied to the talar head lesions is unknown.

Similar principles were used for arthroscopic debridement of talar head lesions as for the treatment of talar dome lesions. The approach we have used does include similar risks and one must consider the relevant surgical anatomy, as risks include damage to local structures including

neurovascular bundle. Great care must be taken in avoiding the neurovascular structures when undertaking arthroscopic debridement of the talonavicular joint.

REFERENCES

1. Herscovici D Jr, Infante AF Jr, Scaduto JM. Case report: extra-articular extrusion of an osteochondral fragment of the talar dome. *Journal of Bone and Joint Surgery*, Apr 2003.
2. Alexander AH, Lichtman DM. Surgical treatment of transchondral talar-dome fractures (osteochondritis dissecans). Long-term follow-up. *J Bone Joint Surg Am* 1980;62(4):646-652.
3. Anderson IF, Crichton KJ, Grattan-Smith T. Osteochondral fractures of the dome of the talus. *American Journal of Bone Joint Surg* 1989 Sep;71(8):1143-1152.
4. Baker CL, Andrews JR, Ryan JB. Arthroscopic treatment of transchondral talar dome fractures. *Arthroscopy* 1986;2(2):82-87.
5. Berlet G, Hyer C, Santrock R, Lee T. Osteochondral lesions of the talus. November 2007 emedicine.com/orthoped/TOPIC638.HTM.
6. Woods K, Harris I. Osteochondritis dissecans of the talus in identical twins. *J Bone Joint Surg Br* Mar 1995;77(2):331.
7. Wheelless C, Milford H, Marchant J, Anderson S, Easley M, Nunley J. Wheelessonline.com/ortho/Talus_Osteochondral_Lesions (2008).
8. Flick AB, Gould N. Osteochondritis dissecans of the talus (transchondral fractures of the talus): review of the literature and new surgical approach for medial dome lesions. *Foot Ankle* 1985 Jan-Feb;5(4):165-185.
9. Robinson DE, Winson IG, Harries WJ, Kelly AJ. Arthroscopic treatment of osteochondral lesions of the talus. *J Bone Joint Surg Br* 2003 Sep;85(7):989-993.
10. Moore K, Dalley A. *Clinical Oriented Anatomy*. 5th ed. Washington, Lippincott Williams and Wilkins 2004.