

Nutcracker Cuboid Fractures are never Isolated Injuries

¹Siddhartha Sharma, ²Mandeep S Dhillon, ³Gaurav Sharma, ⁴Rakesh John

This paper was awarded the 'KP Srivastava Gold Medal' at the annual IFASCON 2013.

ABSTRACT

Background: Cuboid fractures are rare injuries, and treatment methods are ill-defined. The term 'nutcracker' fracture denotes a comminuted fracture of the cuboid which can lead to significant lateral column shortening and pain if treated improperly. The published literature discusses these injuries with implications of such fractures being isolated injuries, and little mention is made of the complex forefoot injuries associated. We believe that such fractures cannot occur in isolation and due attention is often not paid to associated foot instabilities/injuries which may be subtle at times. To validate our hypothesis, we present our evaluation of 12 such cases, all of which were part of a complex foot injury pattern and emphasize on appropriate treatment of associated foot injuries in such cases.

Materials and methods: From the trauma database of a level I trauma center, all cases of cuboid fracture were retrospectively identified, investigated for mechanism of injury, radiographs were reviewed, associated injuries in the foot were documented, and treatment methods applied were recorded.

Results: We identified 12 cases of cuboid fracture. There were 10 males and 2 females, mean age being 20.2 years (14-32 years). No cuboid fracture was found to be an isolated injury, and associated foot injuries included calcaneus fracture in 3 cases, Lisfranc injury in 3 cases and complex midfoot-forefoot injury in 6 cases. Eight cases (66.7%) were open and 4 (33.3%) were closed. Complications included superficial wound infection in 2 cases, deep infection in 1 case and reflex sympathetic dystrophy along with nonunion of the 1st and 2nd metatarsals in one case.

Conclusion: Our results substantiate the hypothesis that nutcracker cuboid fractures cannot occur in isolation and represent one part of a complex, high energy foot injury. In addition to maintaining length of the lateral column and fixing the cuboid, due attention must also be paid to the associated foot injuries, especially the medial column, so as to have a properly aligned, functional and painless foot.

Keywords: Cuboid fracture, Nutcracker fracture, Midfoot injuries.

How to cite this article: Sharma S, Dhillon MS, Sharma G, John R. Nutcracker Cuboid Fractures are never Isolated Injuries. *J Foot Ankle Surg (Asia-Pacific)* 2014;1(1):9-11.

Source of support: Nil

Conflict of interest: None

INTRODUCTION

Cuboid fractures are rare injuries and the annual incidence is reported to be around 1.8/100000.^{1,2} The term 'nutcracker'

^{1,3}Senior Resident, ²Professor, ⁴Junior Resident

¹⁻⁴Department of Orthopedics, Postgraduate Institute of Medical Education and Research, Chandigarh, India

Corresponding Author: Mandeep S Dhillon, Department of Orthopedics, Postgraduate Institute of Medical Education and Research, Chandigarh, India, e-mail: drdhillon@gmail.com

fracture has been used widely in the literature, and denotes a cuboid fracture that is caused by compression of the cuboid between the bases of the 4th and 5th metatarsal and the calcaneus due to plantar-flexion forces.³ Such fractures are invariably associated with shortening of the lateral column of foot and much interest has been generated in the management of such injuries.^{1,3,4}

We believe that such fractures cannot occur in isolation and due attention is often not paid to associated foot instabilities/injuries which may be subtle at times. To validate our hypothesis, we present our evaluation of 12 such cases, all of which were part of a complex foot injury pattern and emphasize on appropriate treatment of associated foot injuries in such cases.

MATERIALS AND METHODS

This was a retrospective, noncomparative study. From July 2011 to June 2013, all cases of foot injuries were identified from the database of a level I trauma center. Of these, cases of cuboid fracture were investigated for mechanism of injury, the radiographs were reviewed, the associated injuries in the foot were documented, and the treatment methods applied were recorded. Cases were classified as per the Orthopedic Trauma Association (OTA) classification as extra-articular (type A), partial-articular (type B) or intra-articular (type C). Functional outcomes were measured by the AOFAS mid-foot score.⁶ Results were graded as excellent (90-100 points), good (80-89 points), fair (70-79 points) and poor (<70 points).⁶

RESULTS

A total of 294 cases of foot injuries were identified in the study period, of which 12 (4.08%) had cuboid fractures. The mean age was 20.2 years (range 14-32 years); the male to female ratio was 5:1 (10 males, 2 females). The mechanism of injury was road traffic accident in seven (58.3%) cases, fall from height in three (25%) and fall of heavy object on the foot in two (16.7%) cases. As per the OTA classification, there were five (41.7%) type B fractures and seven (58.3%) type C fractures. Eight (66.7%) cases were open injuries. Associated injuries included femoral shaft fracture in two cases, tibial shaft fracture in two cases, head injury in one case and urethral injury in one case.

No case of cuboid fracture was an isolated injury. In six (50%) cases, the cuboid fracture was part of a complex

midfoot-forefoot injury, in three (25%) cases there was an associated calcaneus fracture and, in three (25%) cases, there was an associated Lisfranc injury. The lateral column injury was addressed by ligamentotaxis and stabilization with JESS fixator (Fig. 1) in eight cases and K wires in four cases. The medial column injury was addressed by JESS fixator plus K wires in two cases and K wires alone in 10 cases. Unsatisfactory reduction of the medial column (Fig. 2) was noted in four cases. Complications were noted in four cases. Wound infection occurred in three cases, of which two cases were superficial and managed by antiseptic dressings alone; one case has deep infection which necessitated debridement and intravenous antibiotics. Nonunion of the 1st and 2nd metatarsal along with reflex sympathetic dystrophy occurred in one case, for which the patient was referred to the pain clinic and is under follow-up. The average AOFAS mid-foot score at final follow-up was 76.7 (61-84). Following Kitaoka et al, four cases were graded as 'good', 7 as

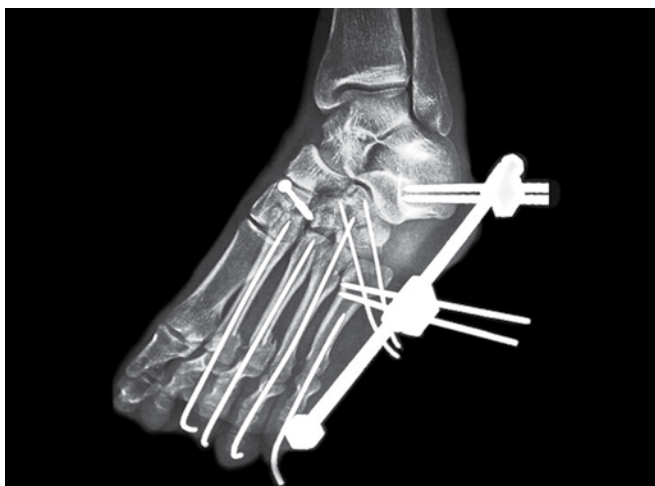

Fig. 1: Postoperative radiograph of a nutcracker cuboid fracture associated with a complex midfoot-forefoot injury. The lateral column length was restored by JESS fixator, K-wires were used to stabilize the metatarsal fracture and metatarsophalangeal dislocations and a lag screw was used to fix the middle cuneiform

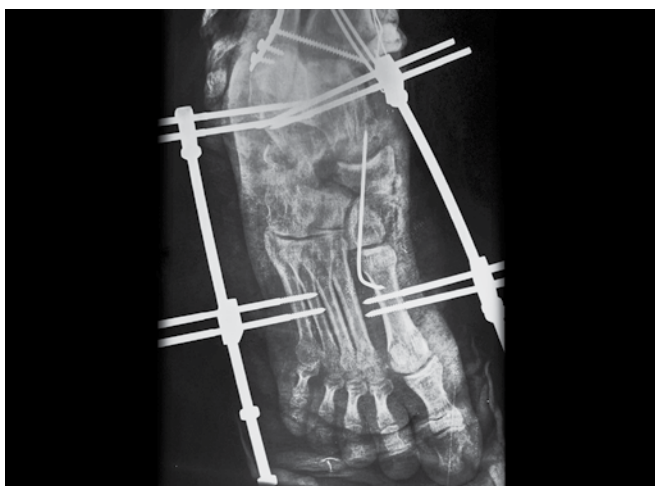


Fig. 2: AP view showing JESS fixators applied to both columns, reduction is nevertheless unsatisfactory

'fair' and 1 as 'poor'. The mean follow-up was 12.7 months (6-22 months).

DISCUSSION

The foot can be thought of as comprising of two columns of almost equal length, a medial column and a lateral column. Therefore, shortening of one column cannot occur without disruption of the other.⁶ Many authors have emphasized on the complex anatomical relationship of the cuboid with the other foot bones and described the possible patho-anatomical mechanisms of a compressed cuboid fracture.^{3,4,7}

The 'nutcracker' fracture was first described by Hermel and Gershon-Cohen³ in 1953. The authors have hypothesized that forces applied to a plantar-flexed foot with the forefoot fixed result in compression of the cuboid between the calcaneus and the bases of 4th and 5th metatarsal.

Sangeorzan et al⁴ have pointed out that the cuboid articulates with the calcaneus, lateral cuneiform and 4th and 5th metatarsals by means of complex ligamentous attachments. Therefore, isolated injuries of the cuboid are extremely uncommon and malunion always results in restricted movement.

Main and Jowett⁷ believe that the cuboid is involved in all movements of the mid-foot and hindfoot; and that compression of the cuboid occurs indirectly as a result of forced hyper-abduction or due to laterally directed forces applied on to a fixed forefoot.

We reviewed the literature on nutcracker fractures and found that in many reports, the 'isolated' injuries, were in fact complex mid-foot injuries and that the authors had focussed on the 'nutcracker' cuboid fracture rather than the complex injury as a whole. A review of literature has been presented in Table 1. An associated foot injury was present in 12 of the 22 (54.5%) cases reviewed.

Although the indications for surgical management of cuboid fractures are ill-defined, most authors agree that fractures with >2 mm displacement, loss of length or evidence of calcaneocuboid subluxations should be managed surgically.^{1,3,4,8}

Most authors have reported good to fair outcomes in their series of cuboid fractures managed surgically. Yu et al¹ reported good results in two cases and fair results in 4 cases in their series of six patients managed by open reduction and internal fixation using dorsolateral miniplates and freeze dried allograft. Sangeorzan et al⁴ reported pain free return to function in all four patients with cuboid fracture managed by open reduction and internal fixation with cancellous screws with K wires and autologous iliac crest bone grafting. Ceroni et al⁸ reported excellent results in two patients with cuboid fracture in whom the cuboid length was restored surgically using allograft and K wires and unsatisfactory outcomes

Table 1: A review of literature on nutcracker cuboid fractures

S. no.	Author	No. of cases	Associated foot injuries (%)	Type of associated foot injuries
1.	Ceroni et al ⁸	4	4 (100)	Avulsion fracture of navicular in 3 cases, burst fracture of navicular in 1 case Multiple cuneiform fractures in all cases Talar head avulsion fracture in 1 case Multiple metatarsal fractures in 3 cases
2.	Hermel et al ³	5	5 (100)	Avulsion fracture of the navicular in all cases
3.	Hunter et al ⁹	1	1 (100)	Avulsion fracture of the navicular
4.	Manoj-Thomas ¹¹	1	1 (100)	Fracture base of 4th metatarsal; Multiple metatarsophalangeal joint dislocations
5.	Sangeorzan et al ⁴	4	—	—
6.	Yu et al ¹	6	—	—
7.	Yu et al ¹⁰	1	1 (100)	Navicular, medial and lateral cuneiform malunion

in the other two cases in their series that were managed conservatively. However, the results in our series were not as good as reported by the other authors. This may be due to the fact that half of the cases in our study had associated injuries and approximately two-thirds were open injuries, reflecting the severe nature of trauma in our series. Furthermore, there were four cases with unsatisfactory medial column reduction; all of these were open cases with severe soft tissue loss with doubtful viability of the foot, necessitating multiple wound debridements and eventual flap coverage. These patients continue to be under our follow-up and will in all probability require surgery in future for pain and deformity. Finally, the one patient in our series who developed reflex sympathetic dystrophy had poor outcome.

To conclude, we would like to emphasize that nutcracker fractures of the cuboid are invariably associated with injuries, to other structures in foot, bony or ligamentous. The associated injury may be subtle at times and may be overlooked initially; therefore a thorough search is warranted before labelling such injuries as 'isolated'. Finally, it is of paramount importance to restore the length of the cuboid and reduce the medial column anatomically so as to achieve excellent functional outcomes.

REFERENCES

1. Yu G, Yu T, et al. Nutcracker fracture of the cuboid: management and results. *Acta Orthop Belg* 78(2):216-219.
2. Court-Brown CM, Zinna S, Ekrol I. Classification and epidemiology of mid-foot fractures. *Foot* 2006;16:138-141.
3. Hermel MB, Gershon-Cohen J. The nutcracker fracture of the cuboid by indirect violence. *Radiology* 1953;60:850-854.
4. Sangeorzan BJ, Swiontkowski MF. Displaced fractures of the cuboid. *J Bone Joint Surg Br* 1990 May;72(3):376-378.
5. Kitaoka HB, Alexander IJ, Adelaar RS, et al. Clinical rating systems for the ankle, hindfoot, midfoot, hallux and lesser toes. *Foot Ankle Int* 1994;15:349-353.
6. Dhillon MS, Nagi ON. Total dislocations of the navicular: are they ever isolated injuries? *J Bone Joint Surg Br* 1999 Sep;81(5):881-885.
7. Main BJ, Jowett RL. Injuries of the midtarsal joint. *J Bone Joint Surg* 1975;57-B:89-97.
8. Ceroni D, V De Rosa, et al. Cuboid nutcracker fracture due to horseback riding in children: case series and review of the literature. *J Pediatr Orthop* 2007;27(5):557-561.
9. Hunter JC, Sangeorzan BJ. A nutcracker fracture: cuboid fracture with an associated avulsion fracture of the tarsal navicular. *AJR Am J Roentgenol* 1996 Apr;166(4):888.
10. Yu G, Yu T, Yang Y, Yuan F. Old nutcracker fracture of cuboid. *Indian J Orthop* 2013 May;47(3):310-312.
11. Manoj-Thomas A, Gadgil A. Nutcracker fracture of the cuboid: a case report. *European Journal of Orthopaedic Surgery and Traumatology* 2006;16(2):178-180.