

# Evaluation of Ankle Tightrope Syndesmosis Fixation

<sup>1</sup>Waheeb AK Al-azzani, <sup>2</sup>Tarique Sabah, <sup>3</sup>Vishal Paringe, <sup>4</sup>Declan O'Doherty

## ABSTRACT

**Introduction:** Ankle sprains are among the most common of bone and joint injuries. Historically, distal tibiofibular syndesmosis injuries have been treated using syndesmosis metal screws to prevent diastasis. However, the use of screws meant that physiological micro-movement between the tibia and fibula was lost which often results in loosening and breaking of the screws. Tightrope fixation was a new technique that has been developed to overcome these complications and allowed some degree of flexibility similar to that offered by natural ligaments. The aim of our study was to evaluate such injuries.

**Materials and methods:** We conducted a retrospective study reviewing all clinical records of cases of patients with injuries of the distal tibiofibular syndesmosis treated with the ankle tightrope (Arthrex Inc) in our institution between January 2008 and January 2011.

**Results:** A total of 42 patients were reviewed. We encountered five cases with complications (12%). Of those: three required removals due to prominent knot, one soft-tissue irritation and one with uncomplicated wound infection.

**Conclusion:** Our study, one of the largest so far evaluating complications of tightrope fixation, demonstrates that one in eight patients treated with tightrope will experience complication.

**Keywords:** Ankle, Syndesmosis, Distal tibiofibular syndesmosis, Instability, TightRope.

**How to cite this article:** Al-azzani WAK, Sabah T, Paringe V, O'Doherty D. Evaluation of Ankle Tightrope Syndesmosis Fixation. *J Foot Ankle Surg (Asia-Pacific)* 2014;1(1):1-4.

**Source of support:** Nil

**Conflict of interest:** None

## INTRODUCTION

Ankle fractures are among the commonest type of fractures in England and Wales, with an incidence of at least 15 per 10,000 per year.<sup>1</sup> In approximately 13% of all ankle fractures as well as 0.5% of all ankle sprains without fracture, there is an associated injury to the distal tibiofibular syndesmosis which, if untreated, leads to instability and pain.<sup>2,3</sup> Widening of the ankle mortise by only 1 mm has been shown to causes a 42% reduction in the contact area of the tibiotalar joint in biomechanical studies. This translates into a marked

increase of the tibiotalar contact pressure and subsequently joint damage. Therefore, early recognition of syndesmosis injuries is extremely important so that the appropriate action is taken to reduce the syndesmosis and maintain this reduction until full healing of ligaments.<sup>4-7</sup>

Traditionally, surgical fixation of the syndesmosis has been achieved using syndesmosis metal screws. However, the use of screws meant that physiological micro-movement between the tibia and fibula, particularly during dorsiflexion of the ankle, was lost which often resulted in loosening and breaking of the screws. Many surgeons routinely remove screws before allowing full weight bearing in order to avoid those complications. However, for this, patients would need to endure another operation. In addition, removal of screws before full ligament healing results in diastasis. Tightrope fixation, a non-absorbable fiberwire suture placed across the syndesmosis looped and tightened through two metal cortical buttons, technique was developed to overcome complications encountered by using metallic screws. This novel technique has been shown to be minimally invasive, requiring only a medial incision, strong enough to resist diastasis but yet allowing for physiological micromotion, allowing for early mobilization and requiring no routine removal.<sup>8-11</sup> However, this novel technique is not without complications. Recent small scale studies have raised concerns about the high rate of implant removal due to significant soft tissue complications, highlighting the need for larger studies to be carried out to ascertain those alarming claims.<sup>3,12,13</sup>

## AIMS AND OBJECTIVES

The purpose of this study was to review patients with injuries of the distal tibiofibular syndesmosis treated with ankle tightrope (Arthrex Inc) assessing rate and types of complications experienced.

## MATERIALS AND METHODS

We conducted a retrospective study reviewing all clinical records of cases of patients with injuries of the distal tibiofibular syndesmosis treated with ankle tightrope (Arthrex Inc) in our institution between January 2008 and January 2011. Patients with no follow-up in our institution were excluded from the study. Determination of diastasis was based on preoperative clinical examination, standard plain

<sup>1</sup>Foundation Trainee, <sup>2,3</sup>Orthopaedic, <sup>4</sup>Consultant

<sup>1-4</sup>Department of Trauma and Orthopedics, University Hospital of Wales, Cardiff, United Kingdom

**Corresponding Author:** Waheeb AK Al-azzani, Foundation Trainee, Department of Trauma and Orthopaedic, University Hospital of Wales, CF 14 4XW, Cardiff, United Kingdom, e-mail: jzm6wa@cf.ac.uk

X-ray, MR imaging or computed tomography as well as using image intensifier screening intraoperatively. Method of fixation was at surgeons' discretion. Concomitant ankle fractures were fixed according to AO-ASIF techniques. The manufacturers recommended surgical techniques were used in all cases.

All patients were immobilized in a nonweight bearing below-knee cast for 6 weeks postoperatively, during which, sutures removal and a review X-ray were done at 3 weeks. Progressive weight-bearing was allowed after 6 weeks given that radiology was satisfactory. Syndesmotic integrity was assessed during follow-up appointments at fracture clinic by using clinical examination and weight-bearing radiographs.

## RESULTS

A total of 42 patients were reviewed. Mean age was 51 years (range 17 to 85). There were 28 males and 14 females. There were associating fractures (93%), including Weber C, B and Maisonneuve fractures, as well as isolated syndesmotic injury without fracture (7%). Mean follow-up was 6 months and mean time to full weight-bearing was 6 weeks. Post-operative X-rays were taken at 3 and 6 weeks in all cases.

We encountered five cases with complications equating to 12% of total number of cases reviewed. Of those, one was soft-tissue irritation, one was uncomplicated wound infection and three required removals due to prominent knot. There were no cases with osteolysis, synostosis or syndesmotic widening.

## DISCUSSION

The distal tibiofibular syndesmosis is a strong fibrous joint formed by two bones linked by four ligaments in a complex

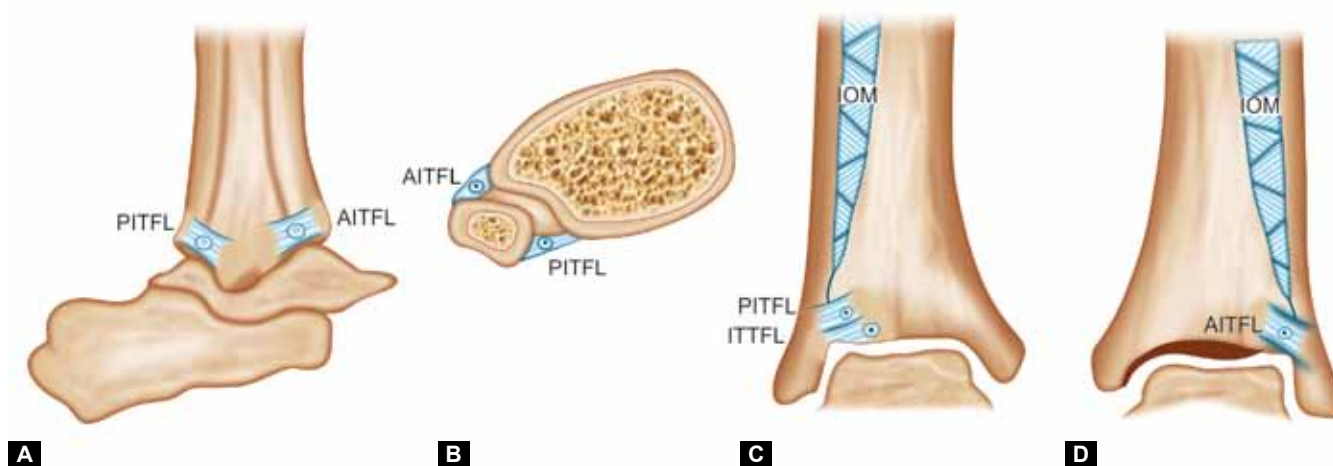
anatomy (Figs 1A to D). Together, these function to prevent diastasis holding the fibula to the tibia as well as allowing for slight separation of malleoli during dorsiflexion at the ankle joint.<sup>2,4,6</sup>

Despite the strength of this joint, it is susceptible to disruption particularly during forced hyperdorsiflexion or external rotation of the foot.<sup>14</sup> Syndesmotic disruption can be concomitant with fractures, such as Weber C and some types of Weber B and Maisonneuve fractures.

Biomechanical studies have shown that widening of the ankle mortise by only 1 mm causes a 42% reduction in the contact area of the tibiotalar joint, which translates into a marked increase in the tibiotalar contact pressure and subsequent joint damage. Therefore, early recognition of syndesmotic injuries is extremely important so that the appropriate action is taken to reduce the syndesmosis and maintain this reduction until full healing of ligaments.<sup>4-7</sup>

Surgical fixation of the syndesmosis is indicated if there is a severe injury rendering the ankle joint unstable easily displaced by physiological forces.<sup>14-16</sup> Historically, surgical fixation using diastasis metal screws has been the method of choice. However, opinions, in the literature, vary widely with regard to metal type, size of screws, number of screws, number of cortices to be engaged, position of screws and the timing of their removal.<sup>2,3</sup> In addition, screw fixation has a number of disadvantages, as a result of excessively rigid fixation, including screw loosening (20%)<sup>8</sup> and breakage (28%),<sup>8</sup> which can be partially prevented by prolonged protected weight-bearing. However, this is also associated with increased stiffness and morbidity. Another disadvantage of using diastasis metal screws is the need for their removal necessitating a second operation.<sup>3,10,11</sup>

An alternative fixation method was to use bio-absorbable screws that require no routine removal. However, this method did not gain popularity among surgeons due to risk



**Figs 1A to D:** Inferior tibiofibular ligaments: (A) lateral view, (B) cross-sectional view, (C) posterior view and (D) anterior view of the main ligamentous structures that support the tibiofibular syndesmosis (PITFL: Posterior-inferior tibiofibular ligament; AITFL: Anterior-inferior tibiofibular ligament; IOM: Interosseous membrane; ITTFL: Inferior transverse tibiofibular ligament)<sup>14</sup>

of loosening, breakage and being absorbed before full ligament healing as well as concerns of the difficulty, or even the impossibility, of removal in case of infection.<sup>11</sup>

Another relatively new and minimally invasive, method based on a suture-button design was the tightrope fixation. The idea was to have an implant that is strong enough to resist diastasis, allows physiological micromotion, allows for early mobilization and does not require routine removal, thus overcoming problems encountered by the use of metallic screws.<sup>11</sup> Tightrope is a nonabsorbable fiberwire suture placed across the syndesmosis looped and tightened through two metal cortical buttons, seems to fit the above criteria. In fact, recent studies have shown earlier weight-bearing, earlier return to work and significantly better mean postoperative American Orthopedic Foot and Ankle scores (AOFAS) in patients treated with tightrope compared to metallic screws.<sup>8-11</sup>

With those advantages in mind, complications have been reported in a total of four studies with an average rate of 20% complication rate. Reported complications included wound infection, soft-tissue irritation, osteolysis, synostosis, syndesmotic widening and prominent knot with the latter being the most common.<sup>3,12,13,17</sup>

However, a key limitation of these studies was the small sample size with the great majority of them with less than 25 patients. Our own experience, in one of the largest study so far evaluating the use of the ankle tightrope, suggest that one in eight patients (12%) with syndesmotic disruption treated with tightrope might experience complications, some requiring removal of the implant. The most common reason for implant removal in our case series was a prominent knot on the lateral aspect (3/5). This was removed on average 8 months postoperation by which time the syndesmosis had healed and required no further treatment. It has been reported that knot prominence may be avoided by burying a longer length of knotted suture behind the fibula.<sup>18</sup> However, this remains to be tested on a large cohort of patients. The second complication was a wound infection (1/5) developed one week postoperation. A swap of the wound grew *Staphylococcus aureus* which was successfully treated with appropriate antibiotics with no further problems. The third complication was soft-tissue irritation in a patient who presented one year post-operatively with pain and swelling around the ankle joint. X-ray showed erosion at the level of syndesmosis and a loose tightrope. Symptoms settled after implant removal.

Our study design was based on a retrospective case series model and, thus, despite our efforts to minimize errors and bias, our findings remain limited. These included reliance on the availability and accuracy of medical records to obtain

data and absence of a control group. Although, selection of tightrope vs metallic screws for treatment was at surgeons' discretion, the large number of surgeons involved may mitigate against selection bias. The strength of our study is in its large sample size which would help to refine previous findings. Longer follow-up, obtaining well-validated functional outcome measures, such as the AOFAS and quality of life scores, in a randomized control study comparing tightrope fixation to metallic screws fixation is highly desirable.

## CONCLUSION

The present study highlights that one in eight patients treated with ankle tightrope fixation of distal tibiofibular syndesmosis disruption might experience a complication; most commonly a prominent knot or soft-tissue irritation requiring a second operation to remove the implant. Patients should be made aware of this before undergoing the procedure. Procedural modifications and design modifications should be sought to minimise the chances of these complications. However, despite these limitations, use of tightrope fixation appears to be more favorable when compared to metallic screws fixation.

## REFERENCES

1. Van Staa TP, et al. Epidemiology of fractures in England and Wales. *Bone* 2001;29(6):517-522.
2. Dattani R, et al. Injuries to the tibiofibular syndesmosis. *J Bone Joint Surg Br* 2008;90-B(4):405-410.
3. Willmott HJ, B Singh, David LA. Outcome and complications of treatment of ankle diastasis with tightrope fixation. *Injury* 2009;40(11):1204-1206.
4. Bauer S, et al. Injuries of the distal lower extremity syndesmosis. *Current Orthopaedic Practice* 2009;20(2):111.
5. Harris J, Fallat L. Effects of isolated Weber B fibular fractures on the tibiotalar contact area. *The Journal of Foot and Ankle Surgery: Official Publication of the American College of Foot and Ankle Surgeons* 2004;43(1):3-9.
6. Hermans JJ, et al. Anatomy of the distal tibiofibular syndesmosis in adults: a pictorial essay with a multimodality approach. *Journal of Anatomy* 2010;217(6):633-645.
7. Ramsey PL, Hamilton W. Changes in tibiotalar area of contact caused by lateral talar shift. *The Journal of Bone and Joint Surgery. American Volume* 1976;58(3):356-357.
8. Cottom JM, et al. Transosseous fixation of the distal tibiofibular syndesmosis: comparison of an interosseous suture and endobutton to traditional screw fixation in 50 cases. *The Journal of Foot and Ankle Surgery: Official Publication of the American College of Foot and Ankle Surgeons* 2009;48(6):620-630.
9. Petsavage J, et al. Tightrope walking: a new technique in ankle syndesmosis fixation. *Radiology Case Reports* 2010;5(1): [Online].
10. Teramoto A, et al. Comparison of different fixation methods of the suture-button implant for tibiofibular syndesmosis injuries. *The American Journal of Sports Medicine* 2011;39(10):2226-2232.

11. Thornes B, et al. Suture-button syndesmosis fixation: accelerated rehabilitation and improved outcomes. *Clinical Orthopaedics and Related Research* 2005;431:207-212.
12. Degroot H, Al-Omari AA, Ghazaly SA El. Outcomes of suture button repair of the distal tibiofibular syndesmosis. *Foot and Ankle International/American Orthopaedic Foot and Ankle Society [and] Swiss Foot and Ankle Society* 2011;32(3):250-256.
13. Treon K, et al. Complications of ankle syndesmosis stabilisation using a tightrope. *J Bone and Joint Surg Br* 2009;93-D(1):62.
14. Mulligan EP. Evaluation and management of ankle syndesmosis injuries. *Physical therapy in sport: Official Journal of the Association of Chartered Physiotherapists in Sports Medicine* 2011;12(2):57-69.
15. McRae R, Esser M. *Practical fracture treatment*. 5th ed. Edinburgh: Elsevier/Churchill Livingstone 2008;447.
16. SportsPhysiotherapist@. Ankle syndesmosis injuries: evidence based diagnosis and management 2011. Available at: <http://www.thesportsphysiotherapist.com/ankle-syndesmosis-injuries-evidence-based-diagnosis-and-management/>.
17. McMurray D, Hornung B, Venkateswaran Z. Walking on a tightrope: our experience in the treatment of traumatic ankle syndesmosis rupture. *Injury Extra* 2008;39:182.
18. Hodgson P, Thomas R. Avoiding suture knot prominence with suture button along distal fibula: technical tip. *Foot and ankle International/American Orthopaedic Foot and Ankle Society* 2011;32(9):908-909.